

Systemic disease or periodontal disease? Distinguishing causes of gingival inflammation: a guide for dental practitioners

Hirschfeld, Josefine; Higham, Jon; Chatzistavrianou, Despoina; Blair, Fiona; Richards, Andrea; Chapple, Iain

DOI:

[10.1038/s41415-019-1050-8](https://doi.org/10.1038/s41415-019-1050-8)

License:

None: All rights reserved

Document Version

Peer reviewed version

Citation for published version (Harvard):

Hirschfeld, J, Higham, J, Chatzistavrianou, D, Blair, F, Richards, A & Chapple, I 2019, 'Systemic disease or periodontal disease? Distinguishing causes of gingival inflammation: a guide for dental practitioners: PART I: immune mediated, autoinflammatory, and hereditary lesions', *British Dental Journal*, vol. 227, no. 11, pp. 961–966. <https://doi.org/10.1038/s41415-019-1050-8>

[Link to publication on Research at Birmingham portal](#)

General rights

Unless a licence is specified above, all rights (including copyright and moral rights) in this document are retained by the authors and/or the copyright holders. The express permission of the copyright holder must be obtained for any use of this material other than for purposes permitted by law.

- Users may freely distribute the URL that is used to identify this publication.
- Users may download and/or print one copy of the publication from the University of Birmingham research portal for the purpose of private study or non-commercial research.
- User may use extracts from the document in line with the concept of 'fair dealing' under the Copyright, Designs and Patents Act 1988 (?)
- Users may not further distribute the material nor use it for the purposes of commercial gain.

Where a licence is displayed above, please note the terms and conditions of the licence govern your use of this document.

When citing, please reference the published version.

Take down policy

While the University of Birmingham exercises care and attention in making items available there are rare occasions when an item has been uploaded in error or has been deemed to be commercially or otherwise sensitive.

If you believe that this is the case for this document, please contact UBIRA@lists.bham.ac.uk providing details and we will remove access to the work immediately and investigate.

Systemic disease or periodontal disease? Distinguishing causes of gingival inflammation: a guide for dental practitioners – PART I: immune mediated, autoinflammatory, and hereditary lesions.

Short title: **Causes of gingival inflammation: Part I**

Authors:

Josefine Hirschfeld¹, Jon Higham², Despoina Chatzistavrianou², Fiona Blair¹, Andrea Richards², Iain Chapple¹

Affiliations:

¹ Department of Periodontology, Birmingham Dental School and Hospital, 5 Mill Pool Way, B5 7EG
Birmingham, UK

² Department of Oral Medicine, Birmingham Dental School and Hospital, 5 Mill Pool Way, B5 7EG
Birmingham, UK

E-mail addresses:

Josefine Hirschfeld: j.hirschfeld@bham.ac.uk

Jon Higham: jon.higham@nhs.net

Despoina Chatzistavrianou: despoina.chatzistavrianou@bhamcommunity.nhs.uk

Fiona Blair: fiona.blair@bhamcommunity.nhs.uk

Andrea Richards: andrea.richards@bhamcommunity.nhs.uk

Iain Chapple: i.l.c.chapple@bham.ac.uk

Correspondence:

Josefine Hirschfeld

Phone: +44 (0) 121 4665114

Fax: +44 (0) 121 625 8815

Abstract

Objectives: Periodontitis and gingivitis remain two of the most common diseases that affect the oral cavity. As they are caused by plaque, effective oral hygiene, elimination of plaque-retentive factors and successful periodontal treatment will result in resolution of gingival and periodontal inflammation. Certain systemic diseases can have a clinical appearance similar to periodontal diseases or exacerbate existing periodontitis/gingivitis and vice versa. This paper aims to provide the dental practitioner with an understanding of the manifestation of systemic diseases to the periodontium and highlights elements in the clinical assessment, which will aid in establishing a correct diagnosis.

Data sources: Additional anamnestic and clinical clues are important for distinguishing between plaque-induced and non plaque-induced lesions. The first part of this compendium covers immune-mediated and hereditary conditions as causes of gingival lesions, which can resemble those caused by dental plaque. The different conditions are presented concisely and exemplified by clinical photographs.

Conclusions: Dental practitioners should be aware of the various manifestations of systemic diseases to the periodontium in order to offer appropriate diagnosis and treatment, which can reduce both patient morbidity and mortality.

Keywords: periodontitis, gingivitis, non plaque-induced inflammation, autoimmunity, hereditary diseases

Introduction

Periodontitis is a complex inflammatory disease that affects the soft and hard periodontal structures (**Figure 1a**). It is a plaque related disease initiated by bacteria, and driven by the host response, genetic predisposition and environmental risk factors. Periodontitis, if left untreated, often leads to progressive destruction of the tooth supporting tissues and tooth loss (1). Typical clinical findings are pocketing and/or gingival recession. Gingivitis on the other hand is characterised by redness and swelling of the keratinised gingiva adjacent to the teeth (**Figure 1b**). In plaque-induced gingivitis, these symptoms resolve after plaque control. As opposed to periodontitis, gingivitis is therefore a reversible disease. There are, however, cases that do not respond to classic plaque control regimes, including establishment of appropriate oral hygiene, scale and polish, administration of chemical plaque control and elimination of plaque-retentive factors. In cases of non-resolving gingival inflammation the underlying cause is often of a systemic nature and careful examination of the oral cavity for other mucosal changes may reveal findings indicative of an underlying systemic condition (2).

Prompt and accurate diagnosis of underlying systemic disease facilitates appropriate referral, investigation and management. It is also important to acknowledge that non-plaque-induced gingival lesions are often colonised and infected by oral bacteria whereby gingival and periodontal inflammation can additionally contribute to disease activity. Thus, plaque control measures may ameliorate such lesions, however, they do not resolve until the systemic cause is targeted. The National Health Service (NHS) UK recommends that patients are seen for dental check-ups between every 3 to 24 months, depending on their oral health and needs. Because of the regular frequency of dental check-ups dental practitioners are in a unique position to facilitate an early diagnosis of systemic diseases, which can manifest in the oral cavity.

This compendium focuses on non-plaque-induced and non-resolving lesions of the keratinised gingiva in dentate patients and aims to aid the practitioner to distinguish those systemic diseases that might be confused with plaque-induced gingival lesions. However, the authors have also included other systemic and related conditions, which commonly manifest to the gingivae, with the aim to provide the reader with a guide to establishing a differential diagnosis. The non-plaque-induced gingival/periodontal lesions described herein are also in accordance with the recently published Consensus Report of Workgroup 1 of the 2017 World Workshop on the Classification of Periodontal and Peri-Implant Diseases and Conditions (3).

The systemic underlying conditions along with oral clinical photographs, demographic data and clinical descriptions are presented in a summary table. In this article, part 1 of this compendium, we review immune mediated, autoinflammatory, and hereditary gingival lesions. In part 2 of the compendium we go on to review cancer related gingival lesions, infective and other causes of gingival inflammation.

1. Anatomy and terminology

1.1 Anatomy of the periodontium

The periodontium consists of five types of tissues:

1. Free gingiva, the tissue collar around the tooth, which forms the gingival crevice and is lined with epithelium, which is non-keratinised on the tooth-facing side and keratinised on the oral cavity-facing side. It is attached to the tooth at its base by the epithelial attachment, the junctional epithelium. The interdental free gingiva is referred to as the interdental papilla, which is knife-edged under healthy conditions.
2. Attached gingiva, the tissue adjacent to the free gingiva, which is keratinised and firmly attached to the underlying bone structure.
3. Alveolar mucosa, the area beyond the mucogingival junction, which is less firmly attached and non-keratinised. The mucogingival junction, a scalloped line, divides attached gingiva and alveolar mucosa.
4. Alveolar bone consisting of dense cortical plates and cancellous bone as well as of the lamina dura, the wall of the socket.
5. Periodontal ligament, which is attached to the lamina dura as well as to the cementum of the tooth, consists of apical, oblique, horizontal, alveolar crest and interradicular fibres as well as of blood and lymphatic vessels and nerves.

1.2 Plaque-induced gingival lesions

The oral cavity is habitat to several hundred microbial species including bacteria, viruses and fungi. The periodontium is a unique point of challenge in the body, as the tooth-bone interface constitutes a potential port of entry for microorganisms, whereas all other surfaces of the gastro-intestinal tract provide a closed epithelial layer, which eliminates colonising bacteria by epithelial shedding. Thus, if microorganisms on tooth surfaces are allowed to overgrow in the form of a biofilm (plaque), or

calculus, an inflammatory response of the periodontal and gingival tissues is initiated. Plaque-induced gingivitis is characterised by redness and swelling, but is fully reversible by eliminating biofilms from the tooth surfaces. Periodontitis is accompanied by pocket formation in the area of the junctional epithelium, in an attempt by the host immune cells to eliminate the biofilm by releasing toxic enzymes, proteins and reactive oxygen species. Nevertheless, the pocket environment provides excellent growth conditions for anaerobic bacteria, thereby driving inflammation and host-mediated tissue destruction. Only if biofilms and calculus are effectively removed from the pockets can tissue repair take place. An important distinguishing feature of plaque-induced gingival lesions is that, with the exception of necrotising and ulcerative forms, they are usually painless whereas non-plaque-induced gingival lesions are often symptomatic.

1.3 Gingival enlargement

Gingival enlargement or overgrowth (**Figure 2**) is encountered in a variety of systemic and related conditions including orofacial granulomatosis (see **2.3.1**), granulomatosis with polyangiitis (see **2.4**), neutropenia (see **2.6**), plasma cell gingivitis (see **2.7**), hereditary gingival fibromatosis and idiopathic gingival enlargement (see **3.1**), drug-induced gingival enlargement (see Part **2: 6.1**), scurvy (see Part **2: 6.2**) and mouth breathing (see Part **2: 7.1**). It can also occur in plaque-induced gingivitis and periodontitis, especially in adolescents, pregnancy, and necrotising/ulcerative forms of these diseases. Distinguishing the cause can therefore be challenging but the medical history, extent of gingival swelling, presence of inflammation, and response to periodontal intervention can help in differentiating a diagnosis. An important distinguishing feature of some but not all of the systemic conditions in which gingival enlargement occurs is involvement of both the attached and unattached gingivae sometimes termed a “full-width” or “full-thickness” gingivitis. Involvement of the unattached gingivae can be seen in orofacial granulomatosis, plasma cell gingivitis, and polyangiitis with granulomatosis.

1.4 Desquamative gingivitis

Desquamative gingivitis (DG) (**Figure 3**) is a clinical descriptor rather than a diagnosis. Several mucocutaneous pathologies, including pemphigus vulgaris (see **2.1**), pemphigoid and erythema multiforme (see **2.2**), lichen planus and lupus erythematosus (see **2.5**), allergic reactions (see **2.7**) and drug-induced lesions (see Part **2: 6.1**), can result in desquamative gingivitis. Widespread desquamation and/or erosion of the attached gingiva of the teeth is considered the chief characteristic

feature of desquamative gingivitis, it often affects the buccal and labial gingivae but can also occur in the palatal and lingual gingivae. Similarly to full-thickness gingival enlargement, DG is often but not always contiguous with involvement of the adjacent unattached gingivae and **sulcus** mucosa, which should alert the practitioner to the possibility of an alternative diagnosis. In addition to the underlying immune-inflammatory condition driving the desquamative gingivitis dental plaque is an important aggravating factor. It is often difficult to distinguish the cause of DG on purely clinical grounds and histology and immunologic testing are usually necessary to establish a diagnosis (4).

2. Immune-mediated and autoinflammatory gingival lesions

2.1 Pemphigus vulgaris

Pemphigus vulgaris (PV) is an autoimmune blistering disease affecting the skin and mucous membranes (**Figure 4**). Oral lesions usually appear before skin lesions, and in many cases the oral cavity remains the only site affected. Autoantibodies are directed against desmosomes (epithelial adhesion proteins) that bind stratified squamous epithelial cells together (5). In common with other vesiculobullous diseases oral PV presents as shallow oral ulceration, preceded by fluid-filled blisters, which are rarely seen clinically due to their fragility. PV can affect any mucosal surfaces and desquamative gingivitis is a common feature. The preliminary diagnosis is based on the clinical presentation and confirmed by histology. PV can be life threatening, particularly in cases with extensive cutaneous involvement, by means of secondary infection leading to septicaemia. Early diagnosis and management can prevent this complication (6). However, treatment particularly with high dose corticosteroids can lead to significant and potentially life-threatening complications including diabetes, cardiovascular disease, peptic ulcers, adrenal insufficiency, and infection (7).

2.2 Pemphigoid

Pemphigoid is a group of vesiculobullous diseases and is a type of immune-mediated sub-epithelial blistering disease (IMSEBD). These diseases are mediated by a variety of autoantibodies that target the extracellular components that link the basement membrane to basal epithelial cells or to the lamina propria (8). A number of IMSEBD can affect the oral cavity including dermatitis herpetiformis, toxic epidermal necrolysis / erythema multiforme, chronic bullous dermatosis of childhood, and pemphigoid variants. Pemphigoid variants include gestational pemphigoid, bullous pemphigoid, and mucous membrane pemphigoid (MMP). **Additionally**, acquired epidermolysis bullosa and linear IgA

disease are now thought to be variants of MMP (9, 10). Of the pemphigoid variants, mucous membrane pemphigoid (MMP) most commonly affects the oral cavity, with approximately 85 per cent of affected patients having oral involvement (**Figure 5**). When affecting the gingiva, mucous membrane pemphigoid commonly presents as desquamative gingivitis (11). Additionally MMP can affect a variety of extraoral sites including the ocular, nasal, nasopharyngeal, anogenital, laryngeal, and oesophageal mucosa and can also rarely involve the skin. Ocular involvement is of particular concern as this results in scarring which can eventually lead to blindness in the affected eye (12). Although this disorder has an unclear aetiology, pemphigoid-like lesions can occasionally be drug-induced. There is no standard treatment protocol for the management of patients with MMP. The treatment strategies depend on the age of the patient, comorbidities, severity of the disease and the site involved, and may include the administration of corticosteroids, antimetabolites or antibiotics. Plaque control measures can play an important role in controlling oral inflammation in this condition (13).

2.3 Orofacial granulomatosis and related conditions

Orofacial granulomatous inflammation can occur in a variety of disparate conditions including inflammatory bowel disease, particularly Crohn's disease, sarcoidosis, Melkersson-Rosenthal syndrome, and tuberculosis and other mycobacterial infections. Cases can also occur without any apparent association with an underlying systemic disease in which case it might be thought of as idiopathic orofacial granulomatosis (14). Although the aetiopathogenesis of these conditions is varied or indeed unknown, we have grouped these disorders together based on their common clinical presentation to facilitate discussion.

2.3.1 (Idiopathic) orofacial granulomatosis

Orofacial granulomatosis (OFG) is a rare, granulomatous inflammatory disorder that is characterised by persistent enlargement of the soft oral and perioral tissues and has an unknown **aetiology**. Importantly, an onset of OFG during childhood may predict future development of Crohn's disease (15). Affected patients typically present with persistent painless swelling of the lips (cheilitis granulomatosa), indurated tag-like lesions, cobblestoning, linear ulceration, and mucogingivitis. One of the characteristic features of the hyperplastic gingivitis seen in OFG is that it affects the attached and

unattached gingivae (full-thickness gingivitis). The mechanism of the enlargement is granulomatous inflammation. The best treatment of this condition and its prognosis are uncertain.

Melkersson-Rosenthal syndrome, a neurological disorder, is characterised by orofacial swelling analogous to OFG, lower motor neurone facial palsy, and less commonly, fissured tongue. The facial palsy tends to be unilateral and may be indistinguishable from Bell's palsy. (16).

2.3.2 Inflammatory bowel diseases

Oral manifestations of the inflammatory bowel diseases Crohn's disease and ulcerative colitis have been reported to affect up to 60% of the affected patients (17, 18). Crohn's disease is a polygenic autoinflammatory syndrome and which can affect any part of the gastrointestinal tract, including the mouth, although a majority of cases involve the terminal ileum. Orofacial granulomatosis is the commonest orofacial manifestation of this disease, but aphthous stomatitis is also occasionally seen in both CD and UC, however this is a non-specific finding.

Pyostomatitis vegetans is most commonly encountered in patients with ulcerative colitis (UC) but has occasionally been reported in patients with CD. It is a chronic mucocutaneous ulcerative disorder consisting of multiple miliary white or yellow pustules with an erythematous and oedematous mucosal base (**Figure 6**). The pustules can rupture and coalesce to form linear or "snail-track" ulcers. The most frequently involved regions of the oral cavity are the labial gingiva and the labial and buccal mucosa, the tongue and floor of the mouth are rarely involved but it can affect almost all parts of the oral cavity (18, 19).

2.3.3 Sarcoidosis

Sarcoidosis is a chronic systemic disease of unknown aetiology and is characterised by an accumulation of epithelioid granulomas. Sarcoidosis affects multiple organs, especially the lungs, lymph nodes, skin and eyes. The salivary glands are frequently involved, sometimes resulting in xerostomia or bilateral parotid swelling, the combination of parotid swelling, fever, and anterior uveitis is known as uveoparotid fever or Heerfordt syndrome. Oral sarcoidosis is rare and the prevalence is unknown, while the treatment remains controversial and may range from oral glucocorticoids to surgical excision (20). Oral mucosal presentations are varied but include orofacial granulomatosis and localised erythematous swelling which can affect any oral mucosal site including the gingivae (21) (**Figure 7**).

2.4 Granulomatosis with polyangiitis

Granulomatosis with polyangiitis, previously known as Wegener's granulomatosis, is a rare systemic disorder that can affect all areas of the body, including the oral cavity. It is a form of vasculitis that affects small- and medium-size vessels in many organs. Those with the disease require long-term immunosuppression, as otherwise this condition is lethal. The typical oral manifestations occur as gingival erosions and ulcerations, which often appear hyperplastic, leading to the typical clinical presentation of a "strawberry gingivitis". Oral involvement in granulomatosis with polyangiitis has been reported in 10–62 per cent, but oral involvement as the first sign of the disease is found in only 2 per cent of cases (22) (**Figure 8**).

2.5 Oral lichen planus

Lichen planus is a mucocutaneous disorder, which commonly affects the skin and skin appendages (including scalp and nails), oral mucosa, and genitalia. Oesophageal, ocular, laryngeal, nasal, and urinary tract mucosa involvement have also rarely been reported. The epithelial damage is immunologically mediated by cytotoxic T-cells directed against basal keratinocytes and results in vacuolar degeneration and lysis of basal cells. It is not a classical autoimmune disorder and is probably best typified as an inflammatory disease. Its aetiology is poorly understood but a variety of factors have been suggested including genetic, physiological, systemic disease, and hypersensitivity but there is currently no consensus (23). Oral lichen planus (OLP) is one of the most common oral mucosal diseases (24). Gingival involvement (desquamative gingivitis) is very frequently observed, and the disease is characterised by a high variability in clinical appearance and symptoms (**Figure 9**). There are several recognised clinical types including reticular, papular, plaque-like, atrophic, erosive/ulcerative, and rarely bullous variants. Additionally, oral lichenoid lesions including lichenoid contact lesions, lichenoid drug reactions, lichenoid lesions of graft versus host disease and lichenoid interface mucositis, seen in certain forms of lupus, can confuse the diagnosis. In common with many immune-inflammatory oral mucosal diseases, a synergy with periodontal inflammation **exists**, which can influence disease activity. Therefore patients with OLP require appropriate periodontal management, in combination with systemic evaluation, and topical or systemic immunosuppression/modulation (25).

2.6 Neutropenia

The neutrophil is a polymorphonuclear immune defence cell and is the principal cell of the innate immune system. It therefore plays an important role in responding to infection through a diverse array of killing mechanisms including degranulation, respiratory burst resulting in the release of reactive oxygen species, and extrusion of their cytosol and nuclear chromatin as neutrophil extracellular traps. Additionally, as the first responder to microbial ingress the neutrophil helps orchestrate the immune-inflammatory response to infection (26).

As stated in section 1.2, the oral cavity is a unique environment in the body as there is a break in the integument at the tooth-bone / mucosa-tooth interface, which constitutes a potential direct entry port for microorganisms. As such the oral cavity has long been recognised as a site of particular relevance in individuals with immune defects, and this is commonly the case in those with neutropenia.

Neutropenia is defined as a paucity or defective function of neutrophils, and there are several causes of neutropenia including primary forms (chronic benign neutropenia, cyclical neutropenia, and other congenital and familial neutropenias) and secondary forms (iatrogenic, aplastic anaemia, leukaemia, connective tissue disease, malignancies, and infections) all of which result in underproduction of neutrophils in the bone marrow. Neutropenia can also result from increased destruction of neutrophils (hypersplenism and immune neutropenia) and is rarely due to congenital immune defects (leukocyte adhesion deficiency, Chediak-Higashi syndrome, hyper-IgE syndrome, recurrent infection syndrome, and chronic granulomatous disease) (27, 28). All forms of neutropenia can result in oral mucosal pathology, primarily aphthous stomatitis and aggressive forms of gingivitis, which can be hyperplastic in nature (29, 30) (**Figure 10**).

Treatment is varied and depends on the cause of the neutropenia but can include granulocyte-colony stimulating factor (G-CSF), prophylactic use of antibiotics and antifungals, interferon-gamma, allogeneic bone marrow transplantation, gene therapy, intravenous immunoglobulins, corticosteroids and other immunomodulatory or immunosuppressive therapies.

2.7 Plasma cell gingivitis

Plasma cell gingivitis (**Figure 11**) is a rare and benign condition, which is sometimes accompanied by cheilitis or glossitis ("plasma-cell gingivostomatitis"). It may represent a sub-type of plasma cell orofacial mucositis, which can be life threatening when it affects the airway and includes diverse entities such as Zoon's balanitis / vulvitis, which affect the genital mucosa, but may also be a separate

disease entity. Other terms that have been used to describe this condition are idiopathic gingivostomatitis, atypical gingivostomatitis, allergic gingivostomatitis and plasmacytosis. The clinical presentation is that of erythematous mucosa with papillomatous, cobblestone, nodular, or granulomatous enlargement and it is histologically characterised by a dense plasma cell infiltrate (31). It may or may not involve the free gingival margin and can also be a localised lesion. Its aetiology is poorly understood but plasma cell gingivitis has been reported to be associated with hypersensitivity reactions to substances such as toothpaste and chewing gum ingredients, mint, pepper and cinnamon and in these cases resolution follows cessation of the offending allergen (32). However, beyond this there is currently no consensus on management of the disease.

3. Hereditary conditions

3.1 Hereditary gingival fibromatosis and idiopathic gingival hyperplasia

Hereditary gingival fibromatosis is a rare, mostly autosomal dominant disease, which can develop as an isolated disorder or a feature of a syndrome. It is a benign oral condition characterised by slow and progressive enlargement of both maxillary and mandibular attached gingiva. It is commonly associated with hypertrichosis (excess hair growth) as well as with epilepsy and intellectual disability (33). A progressive fibrous enlargement of the gingiva is a feature of idiopathic hyperplasia/fibromatosis of the gingiva (**Figure 12**). Gingival fibromatosis may exist as an isolated abnormality or as part of a syndrome such as Laband syndrome (34). The exact cause of the disease is unknown, however, involvement of platelet-derived growth factor isoforms and its receptor as well as qualitative and quantitative differences in **tumour** growth factor-beta isoforms and receptor expression by fibroblasts have been suggested (35, 36).

Conclusion

In this article, the first part of this compendium, we have reviewed immune-mediated, autoinflammatory, and hereditary gingival lesions, supported by epidemiological data, clinical descriptions and photographs. Several of these systemic conditions can have a similar clinical presentation to periodontitis and gingivitis or exacerbate existing disease. On the other hand, plaque-induced inflammation often worsens non plaque-induced conditions, which can make it more difficult to distinguish both. At the same time, dental practitioners need to be aware that oral manifestations of

systemic diseases can impair oral hygiene abilities in affected patients. Those lesions which are accompanied by pain, are non-resolving or show a morphology atypical of a classic plaque-induced gingival lesions, should encourage dental practitioners to refer their patient to a specialist unit. A full discussion of both part 1 and part 2 of this compendium is included in part 2: cancer related, infective, and other causes of gingival pathology. Readers are therefore referred to this paper.

Declaration of interests

The authors declare no conflict of interest with regard to this manuscript.

Acknowledgments

The authors would like to thank Mr Mutahir Rahman at the Department of Periodontology of the Birmingham Dental School and Hospital for his permission to use clinical photographs. We further thank our patients for their consent to utilise their clinical photographs for this publication.

References

1. Hajishengallis G. Periodontitis: from microbial immune subversion to systemic inflammation. *Nat Rev Immunol* 2015; **15(1)**:30-44.
2. Chi AC, Neville BW, Krayer JW, Gonsalves WC. Oral manifestations of systemic disease. *Am Fam Physician* 2010; **82(11)**:1381-1388.
3. Chapple ILC, Mealey BL, Van Dyke TE, Bartold PM, Dommisch H, Eickholz P, et al. Periodontal health and gingival diseases and conditions on an intact and a reduced periodontium: Consensus report of workgroup 1 of the 2017 World Workshop on the Classification of Periodontal and Peri-Implant Diseases and Conditions. *J Periodontol* 2018; **89(Suppl 1)**:S74-s84.
4. Al-Abeedi F, Aldahish Y, Almotawa Z, Kujan O. The Differential Diagnosis of Desquamative Gingivitis: Review of the Literature and Clinical Guide for Dental Undergraduates. *J Int Oral Health* 2015; **7(Suppl 1)**:88-92.
5. Black M, Mignogna MD, Scully C. Number II. Pemphigus vulgaris. *Oral Dis* 2005; **11(3)**:119-130.

6. Huang Y-H, Kuo C-F, Chen Y-H, Yang Y-W. Incidence, Mortality, and Causes of Death of Patients with Pemphigus in Taiwan: A Nationwide Population-Based Study. *J Invest Dermatol* 2012; **132(1)**:92-97.
7. McMillan R, Taylor J, Shephard M, Ahmed R, Carrozzo M, Setterfield J, et al. World Workshop on Oral Medicine VI: a systematic review of the treatment of mucocutaneous pemphigus vulgaris. *Oral Surg Oral Med Oral Pathol Oral Radiol* 2015; **120(2)**:132-142.e61.
8. G DZ, M C, LS C. Urban legend series: mucous membrane pemphigoid. *Oral Dis* 2014; **20(1)**:35-54.
9. Chan LS, Ahmed AR, Anhalt GJ, Bernauer W, Cooper KD, Elder MJ, et al. The first international consensus on mucous membrane pemphigoid: definition, diagnostic criteria, pathogenic factors, medical treatment, and prognostic indicators. *Arch Dermatol* 2002; **138(3)**:370-379.
10. C SC. PL6□Sub-epithelial vesiculobullous disorders: treatment now and on the horizon. *Oral Dis* 2006; **12(s1)**:2-2.
11. Neff AG, Turner M, Mutasim DF. Treatment strategies in mucous membrane pemphigoid. *Ther Clin Risk Manag* 2008; 4(3):617-626.
12. Chan LS. Ocular and oral mucous membrane pemphigoid (cicatricial pemphigoid). *Clin Dermatol* 2012; **30(1)**:34-37.
13. Hasan S. Desquamative gingivitis - A clinical sign in mucous membrane pemphigoid: Report of a case and review of literature. *J Pharm Bioallied Sci* 2014; **6(2)**:122-126.
14. Tilakaratne WM, Freysdottir J, Fortune F. Orofacial granulomatosis: review on aetiology and pathogenesis. *J Oral Pathol Med* 2008; **37(4)**:191-195.
15. Alawi F. An Update on Granulomatous diseases of the oral tissues. *Dent Clin North Am* 2013; **57(4)**:657-671.
16. Critchlow WA, Chang D. Cheilitis Granulomatosa: A Review. *Head Neck Pathol* 2014; **8(2)**:209-213.
17. Orphanet Report Series (Rare Disease Collection). 2018. Online information available at http://www.orpha.net/orphacom/cahiers/docs/GB/Prevalence_of_rare_diseases_by_decreasing_prevalence_or_cases.pdf (accessed May 2019).
18. Lankarani KB, Sivandzadeh GR, Hassanpour S. Oral manifestation in inflammatory bowel disease: A review. *World J Gastroenterol* 2013; **19(46)**:8571-8579.

19. Mortada I, Leone A, Gerges Geagea A, Mortada R, Matar C, Rizzo M, et al. Oral manifestations of inflammatory bowel disease. *J Biol Regul Homeost Agents* 2017; **31(3)**:817-21.
20. Gupta S, Tripathi AK, Kumar V, Saimbi CS. Sarcoidosis: Oral and extra-oral manifestation. *J Indian Soc Periodontol* 2015; **19(5)**:582-585.
21. Poate TW, Sharma R, Moutasim KA, Escudier MP, Warnakulasuriya S. Orofacial presentations of sarcoidosis--a case series and review of the literature. *Br Dent J* 2008; **205(8)**:437-442.
22. Hanisch M, Fröhlich LF, Kleinheinz J. Gingival hyperplasia as first sign of recurrence of granulomatosis with polyangiitis (Wegener's granulomatosis): case report and review of the literature. *BMC Oral Health* 2017; **17**:33.
23. Alrashdan MS, Cirillo N, McCullough M. Oral lichen planus: a literature review and update. *Arch Dermatol Res* 2016; **308(8)**:539-551.
24. McCartan BE, Healy CM. The reported prevalence of oral lichen planus: a review and critique. *J Oral Pathol Med* 2008; **37(8)**:447-453.
25. Gupta S, Jawanda MK. Oral Lichen Planus: An Update on Etiology, Pathogenesis, Clinical Presentation, Diagnosis and Management. *Indian J Dermatol* 2015; **60(3)**:222-229.
26. Nathan C. Neutrophils and immunity: challenges and opportunities. *Nat Rev Immunol* 2006; **6(3)**:173-182.
27. Schwartzberg LS. Neutropenia: Etiology and Pathogenesis. *Clin Cornerstone* 2006; **8**:S5-S11.
28. Capsoni F, Sarzi-Puttini P, Zanella A. Primary and secondary autoimmune neutropenia. *Arthritis Res Ther* 2005; **7(5)**:208-214.
29. Tirali RE, Yalcinkaya Erdemci Z, Cehreli SB. Oral findings and clinical implications of patients with congenital neutropenia: a literature review. *Turk J Pediatr* 2013; **55(3)**:241-245.
30. Park MS, Tenenbaum HC, Dror Y, Glogauer M. Oral health comparison between children with neutropenia and healthy controls. *Special Care Dent* 2014; **34(1)**:12-18.
31. Galvin S, Bowe C, EM OR, Conlon N, Flint SR, Healy CM. Circumoral plasmacytosis/plasma cell orificial mucositis: a case series and a review of the literature. *Oral Surg Oral Med Oral Pathol Oral Radiol* 2016; **122(3)**:e77-81.
32. Janam P, Nayar BR, Mohan R, Suchitra A. Plasma cell gingivitis associated with cheilitis: A diagnostic dilemma! *J Indian Soc Periodontol* 2012; **16(1)**:115-119.

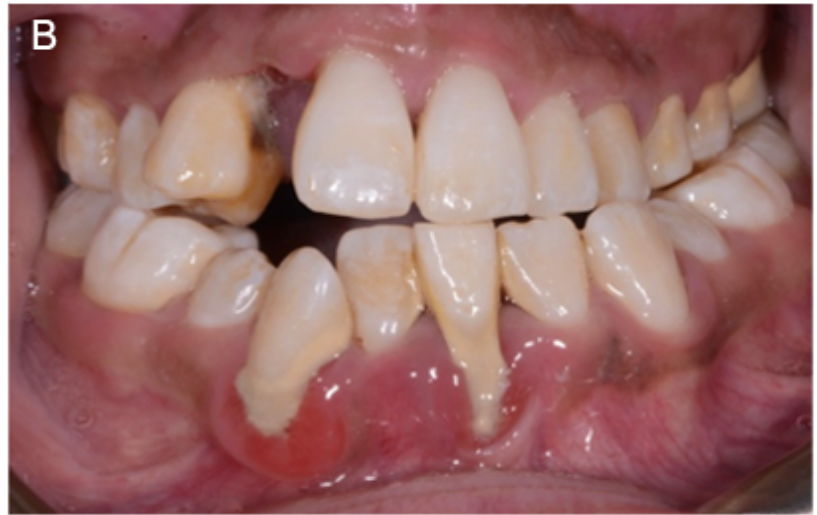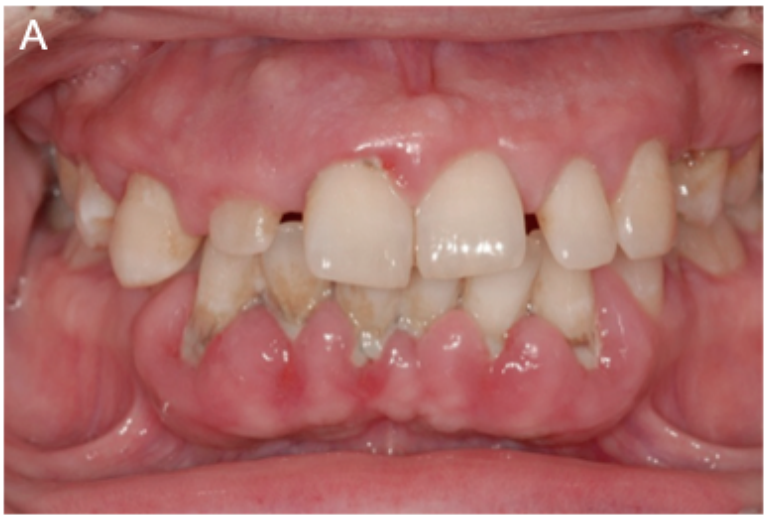33. Dhadse PV, Yeltiwar RK, Pandilwar PK, Gosavi SR. Hereditary gingival fibromatosis. *J Indian Soc Periodontol* 2012;**16(4)**:606-609.
34. Cekmez F, Pirgon O, Tanju IA. Idiopathic Gingival Hyperplasia. *Int J Biomed Sci* 2009;**5(2)**:198-200.
35. Wright HJ, Chapple IL, Matthews JB. TGF-beta isoforms and TGF-beta receptors in drug-induced and hereditary gingival overgrowth. *J Oral Pathol Med* 2001; **30(5)**:281-289.
36. Wright HJ, Chapple IL, Cooper P, Matthews JB. Platelet-derived growth factor (PDGF) isoform and PDGF receptor expression in drug-induced gingival overgrowth and hereditary gingival fibrosis. *Oral Dis* 2006; **12(3)**:315-323.

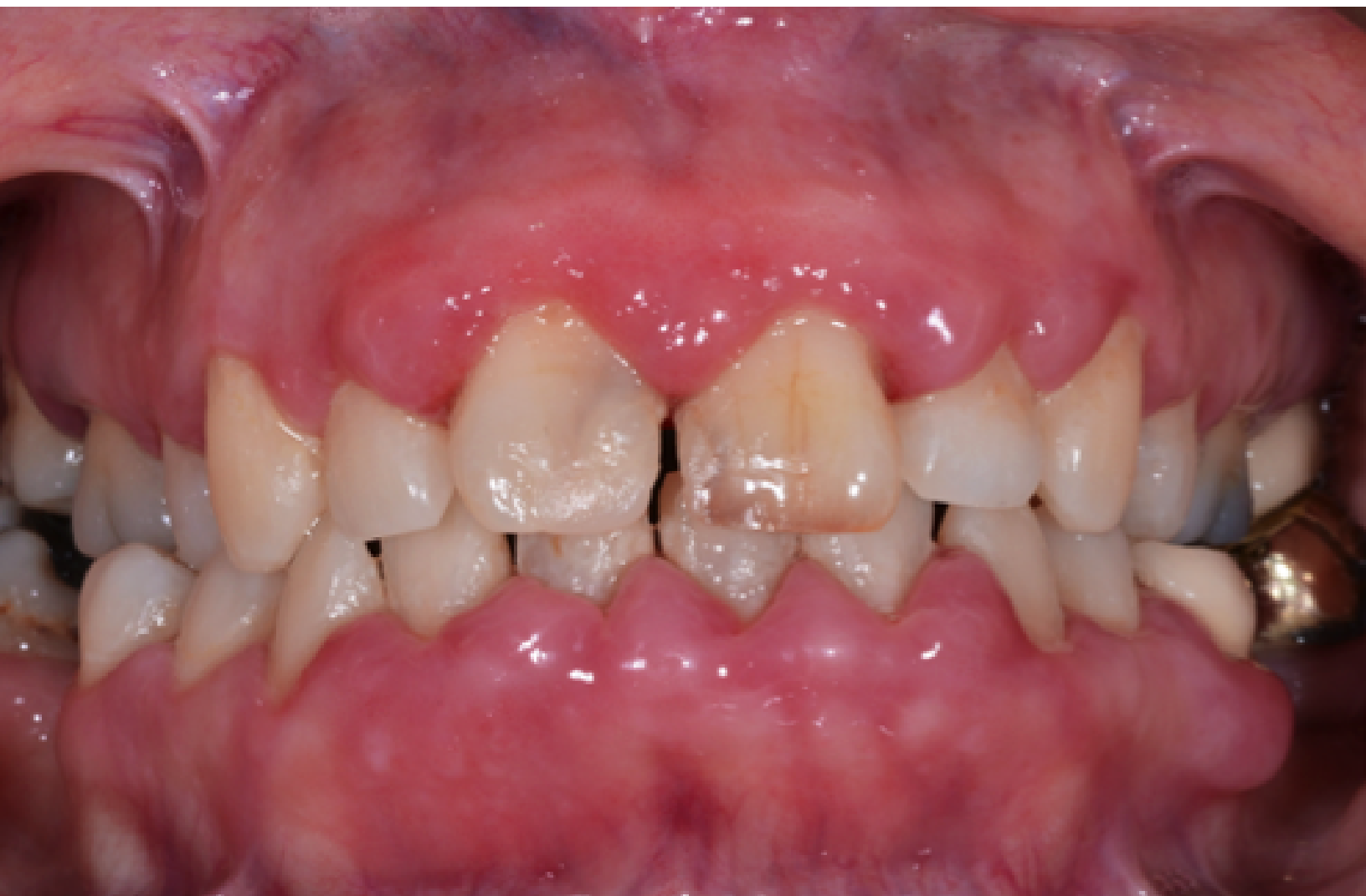Figure legends

Figure 1. Plaque-induced gingival/periodontal diseases. A) Generalised chronic periodontitis with localised gingival swelling, recession formation, tooth loss and pathologic tooth migration. **B)** Plaque-induced generalised gingivitis.

Figure 2. Drug-induced gingival enlargement. Photograph courtesy of Mr Mutahir Rahman, Department of Periodontology, Birmingham Dental School and Hospital, Birmingham (UK).





Figure 3. Desquamative gingivitis in a patient with lichen planus.





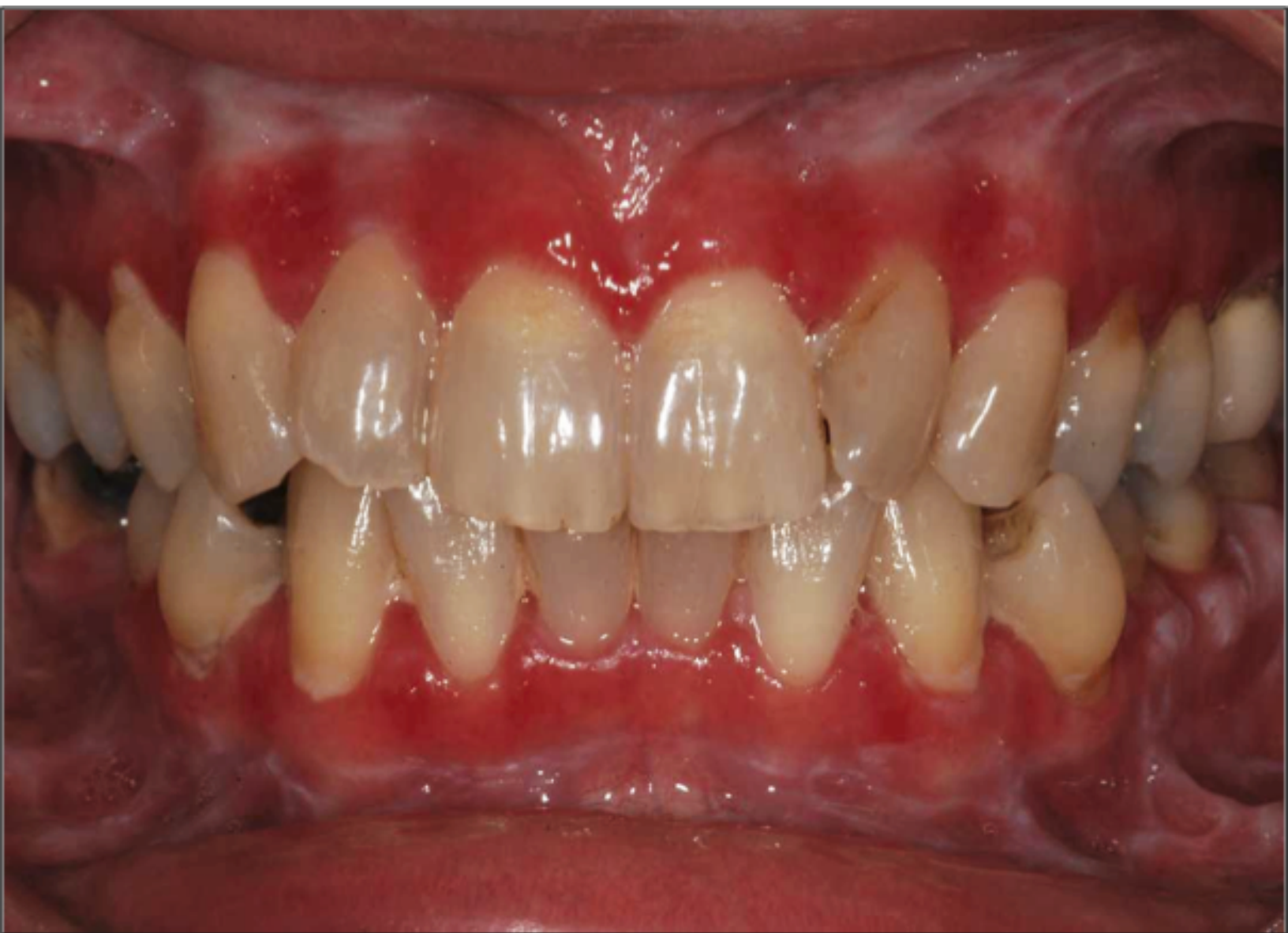






Table 1. Overview of systemic and conditions and non-plaque related causes of gingival and periodontal lesions. All data are derived from the references indicated in the main text as well as from the Orphanet Rare Disease Collection: <http://www.orphadata.org>. Orphanet Report Series (Rare Disease Collection), *Prevalence and incidence of rare diseases: Bibliographic data*: Orphanet, 2018.

Figure	Condition	Demographics and incidence	Image	Clinical description
4	Pemphigus vulgaris	<p>Prevalence: 18/100,000 (in Europe)</p> <p>Age group: usually in the 5th-7th decades, although childhood onset forms have been described.</p> <p>Gender: F>M</p>		<p>Main clinical presentation: ulcers, vesicles/bullae, mucosal erosions. Commonly presents as desquamative gingivitis</p> <p>Pain: moderate to severe</p> <p>Oral tissues involved: palate, buccal mucosae, lips</p>
5	Mucous membrane pemphigoid	<p>Prevalence: unknown</p> <p>Age group: usually in the 5th-7th decades</p> <p>Gender: F>M</p>		<p>Main clinical presentation: ulcers, vesicles/bullae, mucosal erosions. Commonly presents as desquamative gingivitis</p> <p>Pain: mild to severe depending on extent of involvement and disease activity</p> <p>Involvement of other oral tissues: palate, buccal mucosae, tongue (less common)</p>
6	Oral manifestations of inflammatory bowel diseases	<p>Prevalence: 10-60% of those affected by IBD</p> <p>Age group: any</p> <p>Gender: M>F</p>		<p>Main clinical presentation: indurated tag-like lesions, cobblestoning, mucogingivitis, edema, aphthous stomatitis, ulceration, pyostomatitis vegetans, hyperplasia</p> <p>Pain: orofacial granulomatosis: no; pyostomatitis vegetans: variable; oral ulceration: moderate to severe</p> <p>Involvement of other oral tissues: buccal mucosa, lips (swelling and vertical fissuring), perioral tissues (dermatitis), floor of mouth (stag-horning)</p>
7	Sarcoidosis	<p>Prevalence: 12.5/100,000 (worldwide)</p> <p>Age group: any, but more prevalent in the 3rd to 6th decade</p> <p>Gender: M=F</p>		<p>Main clinical presentation: firm swelling or nodular lesions</p> <p>Pain: no</p> <p>Involvement of other oral tissues: lips, hard and soft palate, buccal mucosa, tongue, tonsils, salivary glands</p>

8	Granulomatosis with polyangiitis	<p>Prevalence: 0.85/100,000 (in Europe)</p> <p>Age group: any</p> <p>Gender: F=M</p>		<p>Main clinical presentation: granulomatous/papillary hyperplasia, erosion, ulceration, strawberry gingivitis</p> <p>Pain: no</p> <p>Involvement of other oral tissues: no</p>
9	Oral lichen planus	<p>Prevalence: 1,300/100,000 (worldwide)</p> <p>Age group: between the 4th and 5th decade</p> <p>Gender: F>M</p>		<p>Main clinical presentation: reticular white patterns (striae), keratotic plaques, atrophy, erosions/ulceration, papules, bullae (rare)</p> <p>Pain: mild to severe depending on extent and disease activity</p> <p>Involvement of other oral tissues: every area of the oral mucosa</p>
10	Neutropenia	<p>Prevalence: variable, depending on cause</p> <p>Age group: variable, depending on cause</p> <p>Gender: variable, depending on cause</p>		<p>Main clinical presentation: pronounced gingivitis, often without visible plaque deposits. Recurrent aphthous stomatitis.</p> <p>Pain: variable – usually no</p> <p>Involvement of other oral tissues: all oral mucosal sites</p>
11	Plasma cell gingivitis	<p>Prevalence: unknown</p> <p>Age group: unknown</p> <p>Gender: unknown</p>		<p>Main clinical presentation: erythema, edema, loss of stippling, papillary hyperplasia</p> <p>Pain: sometimes, occasionally accompanied by other sensations</p> <p>Involvement of other oral tissues: palate and buccal mucosa (occasionally)</p>
12	Hereditary gingival fibromatosis	<p>Prevalence: unknown</p> <p>Age group: any</p> <p>Gender: F=M</p>		<p>Main clinical presentation: gingival enlargement</p> <p>Pain: no</p> <p>Involvement of other oral tissues: no</p> <p>Photograph courtesy of Mr Mutahir Rahman, Department of Periodontology, Birmingham Dental School and Hospital, Birmingham (UK)</p>