

## Ring depressions in cattle horncores as indicators of traction use - a cautionary note

Thomas, Richard ; Sykes, Naomi; Doherty, Sean; Smith, David

DOI:

[10.1016/j.ijpp.2018.07.002](https://doi.org/10.1016/j.ijpp.2018.07.002)

License:

Creative Commons: Attribution-NonCommercial-NoDerivs (CC BY-NC-ND)

*Document Version*

Peer reviewed version

*Citation for published version (Harvard):*

Thomas, R, Sykes, N, Doherty, S & Smith, D 2018, 'Ring depressions in cattle horncores as indicators of traction use - a cautionary note', *International Journal of Paleopathology*, vol. 22, pp. 140-142.  
<https://doi.org/10.1016/j.ijpp.2018.07.002>

[Link to publication on Research at Birmingham portal](#)

### **Publisher Rights Statement:**

Checked for eligibility: 12/10/2018

### **General rights**

Unless a licence is specified above, all rights (including copyright and moral rights) in this document are retained by the authors and/or the copyright holders. The express permission of the copyright holder must be obtained for any use of this material other than for purposes permitted by law.

- Users may freely distribute the URL that is used to identify this publication.
- Users may download and/or print one copy of the publication from the University of Birmingham research portal for the purpose of private study or non-commercial research.
- User may use extracts from the document in line with the concept of 'fair dealing' under the Copyright, Designs and Patents Act 1988 (?)
- Users may not further distribute the material nor use it for the purposes of commercial gain.

Where a licence is displayed above, please note the terms and conditions of the licence govern your use of this document.

When citing, please reference the published version.

### **Take down policy**

While the University of Birmingham exercises care and attention in making items available there are rare occasions when an item has been uploaded in error or has been deemed to be commercially or otherwise sensitive.

If you believe that this is the case for this document, please contact [UBIRA@lists.bham.ac.uk](mailto:UBIRA@lists.bham.ac.uk) providing details and we will remove access to the work immediately and investigate.

## Ring depressions in cattle horncores as indicators of traction use – a cautionary note

*Richard Thomas*

School of Archaeology and Ancient History, University of Leicester, University Road, Leicester, LE1 7RH; [rmt12@le.ac.uk](mailto:rmt12@le.ac.uk); [REDACTED]

*Naomi Sykes*

Department of Archaeology, University of Exeter, Exeter, EX4 4QJ.

*Sean Doherty*

Department of Archaeology, University of York, York, YO17EP.

*David Smith*

Classics, Ancient History and Archaeology, University of Birmingham, Edgbaston, Birmingham, B15 2TT.

### Abstract

In this short communication we call attention to the discovery of a ring depression (a circumferential constriction) in the horncore of a feral bull. This discovery casts doubt on the attribution of similar lesions in archaeological deposits as conclusive evidence of 'cord impressions' resulting from yoking or reining cattle for traction. Drawing upon evidence of horncore depressions in other species, we suggest that they reflect metabolic problems following horn development; additional research is required to test this hypothesis.

### Key words

Cattle, Pathology, Traction, Depression, Horncore

### 1 Introduction

Identifying the origin and intensity of cattle use for traction remains a key research focus within zooarchaeology (e.g. Bartosiewicz et al. 1997; de Cupere et al. 2000; Higham et al. 1981; Johannsen 2005, 2006; Issakidou 2006; Thomas 2008). Traditionally, this has been achieved by comparing the age-at-death and sex profile of archaeological assemblages with theoretical models of optimised production. While a high proportion of animals killed towards the end of their growth phase might indicate an emphasis on meat production, the presence of an abundance of older male cattle is typically interpreted as evidence for their exploitation for traction. The problem with this approach is that demographic profiling only provides an assessment of the proximity of theoretical models of optimised production to the patterns observed in archaeological data, rather than direct evidence for products or services (Thomas 2008, 187). Furthermore, it is clear from historical and ethnographic sources that these models are not applicable universally (Groot 2005; Johannsen 2005: 45-7): cows have been used for ploughing since prehistoric times, as the first-century AD Roman author, Columella, makes clear:

“...where food is scarce, the cow must be used for breeding only every other year. This rule is particularly observed where cows are employed for work, in order that, firstly, the calves may have abundance of milk for the space of a year, and, secondly that a breeding cow may not have to bear the burden of work” (*De Re Rustica* VI.24.3-5).

Palaeopathological evidence provides an attractive alternative, because it can provide a direct and abundant source of evidence regarding the use to which animals were put. Cattle did not evolve to pull ploughs and carts and it is well-recognised that the biomechanical strain resulting from such activities can manifest itself in adaptive and degenerative remodelling of the skeleton (Lanyon and Rubin 1985) and is identifiable archaeologically. Most research has focussed on recognising and quantifying the degree of remodelling in the autopodia of cattle (Bartosiewicz et al. 1997; de Cupere et al. 2000; Higham et al. 1981; Thomas 2008), although emphasis has also been placed on other skeletal elements, such as the pelvis (Groot 2005).

In 1991 Milisauskas and Kruk illustrated and described a cattle horncore from the late Neolithic site of Bronocice in southeastern Poland (dated c. 2300-2100 cal BC) which exhibited a ring depression (a complete or partial circumferential constriction) located near the base of the core. Drawing upon historic and ethnographic parallels they described the lesion as a “cord impression” and cited this as evidence that cattle were either horn yoked or that the yoke was attached below the neck but that the reins were tied to the horn (Milisauskas and Kruk 1991, 563). This discovery, alongside material culture, ard marks and other zooarchaeological data, was used to argue that traction technology was present at this site as a manifestation of the ‘secondary products revolution’ (Sherratt 1981). Subsequent discoveries of ring depressions in cattle horncores at other sites have repeated this interpretation (e.g. Onar et al. 2015). Few studies report the frequency of ring depressions; however, two sites from the City of Chester, UK, with large horncore assemblages dating to the 17<sup>th</sup>-19<sup>th</sup> centuries, revealed that fewer than 1% of specimens exhibited such lesions (Table 1).

	Ring depression	“Thumbprint” depression	Total
City Road	11 (0.67%)	16 (0.97%)	1654
Witter Place	10 (0.41%)	13 (0.53%)	2452

Table 1: frequencies of resorptive lesions in the horncores of cattle from two post-medieval sites in Chester, U.K. (Doherty et al. unpublished; Sykes et al. unpublished).

## 2 The Chillingham Specimen

Ongoing research to characterise the nature and frequency of bone pathology in a contemporary herd of feral domestic cattle from Chillingham Park, Northumberland, UK (Fig. 1), has brought to attention a lesion consistent in appearance with the specimen described by Milisauskas and Kruk (1991). The Chillingham herd are documented as feral from at least AD 1645 (Hall 2006). The size of the herd is, and probably always has been, relatively small (currently c.100 head) and the animals are permitted to range freely across a gently-rolling 135-hectare (wood pasture) park through which a stream meanders gently. The animals receive no veterinary intervention, although they are given supplementary feed (hay) during harsh winters. The herd remain healthy despite inbreeding depression caused by their isolation and small population size (Visscher et al. 2001).

The specimen in question comes from a bull aged over 10 years (Halstead 1985). A circular constriction is visible near the base of the horn in the keratinous sheath as well as the underlying bone core (Figs 1-3).

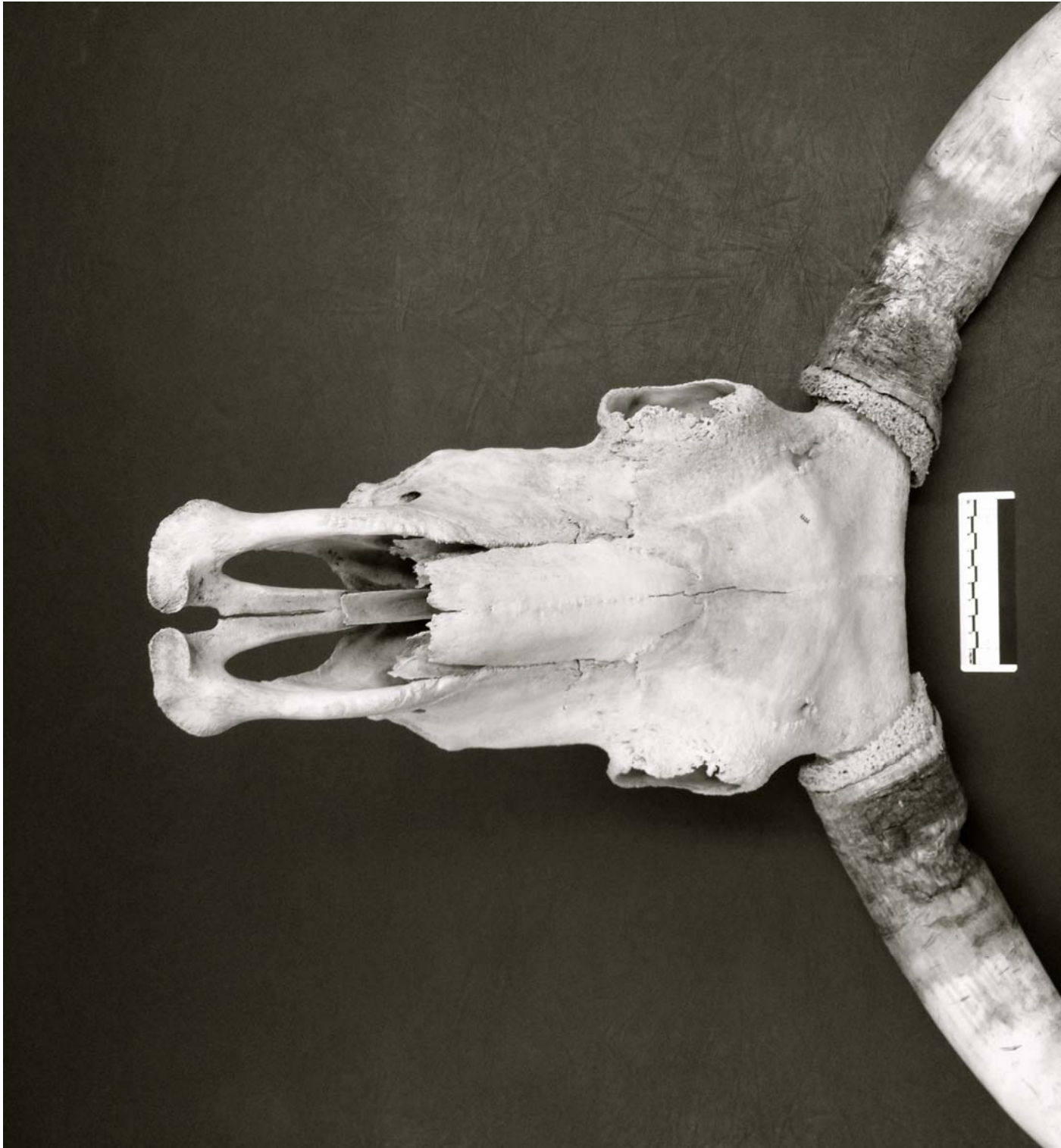

Fig. 1: ring depressions in the horns of a feral bull from Chillingham Park.

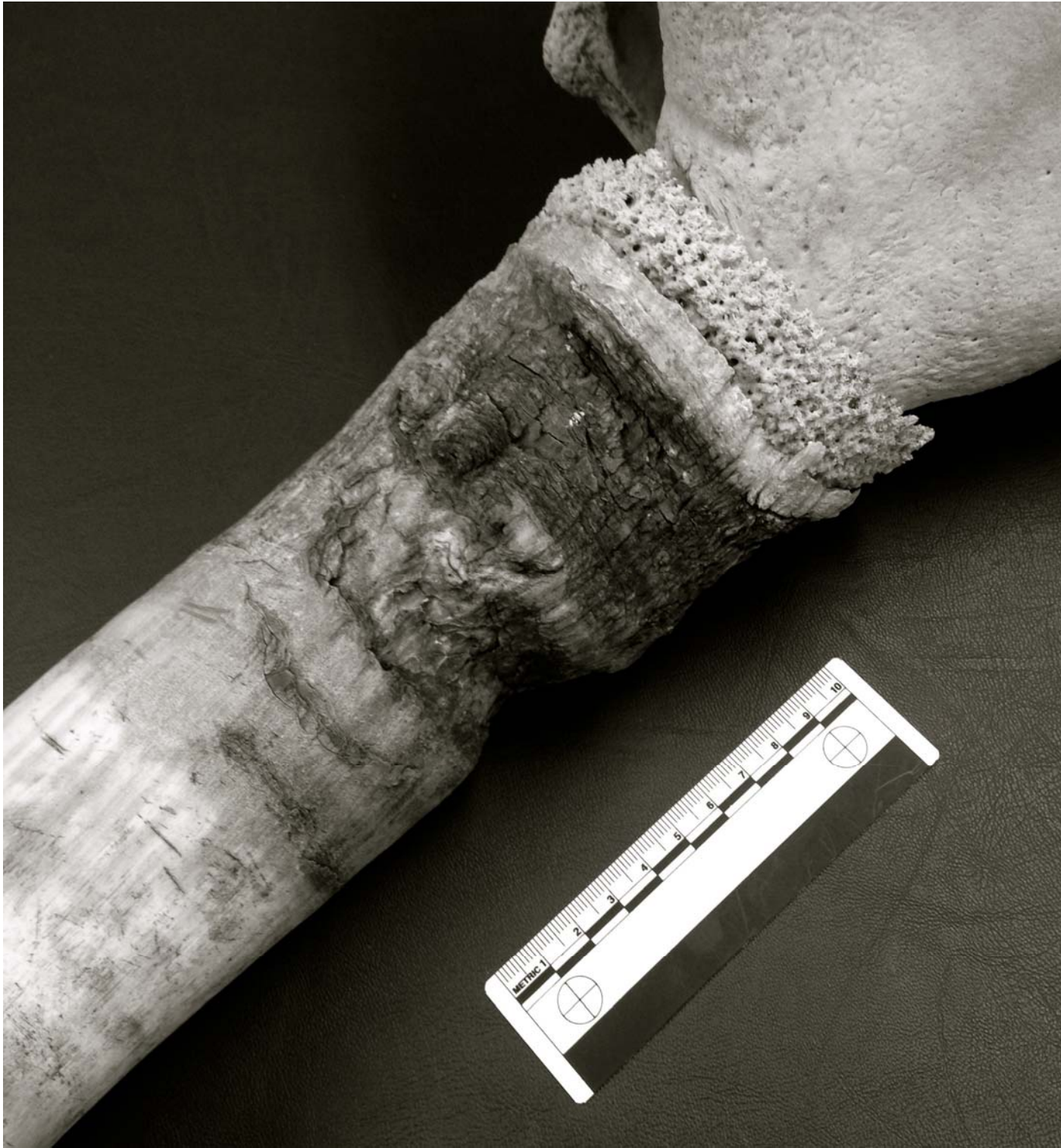

Fig. 2: close-up of ring depression in the left horn of a feral bull from Chillingham Park.

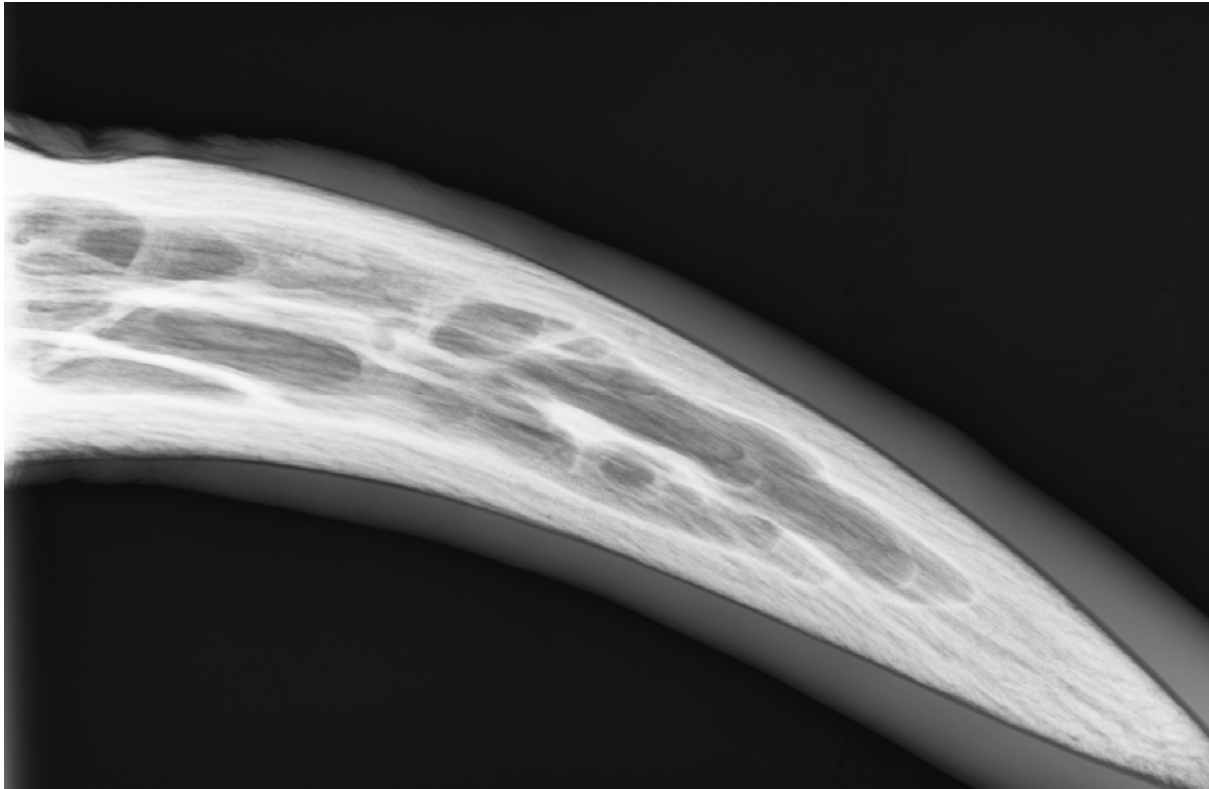


Fig. 3: radiograph of ring depression in the left horn of a feral bull from Chillingham Park.

The occurrence of this lesion in an animal that was never yoked raises doubts concerning the interpretation of Miliskauskas and Kruk (1991). Horncores from animals known to have been yoked/reined by the horns with ropes are certainly required to confirm whether “cord impressions” can result from these practices.

If not a consequence of yoking, it is necessary to consider other potential causes of ring depressions, to establish their potential value for reconstructing past human-animal relationships. Differential diagnosis is challenged by the absence of clinical recognition. Some classes of disease can be excluded, however, based on the appearance of the lesions. For example, neoplasia of the horncore would be characterised by extensive bone destruction within the interior of the horncore (e.g. Gomes et al. 2012). Trauma can also be excluded as a potential cause. While horns serve an important role for cattle in competitive display, they are highly resistant to fracture (Kitchener 1987); notwithstanding their relative rarity, lesions of healed trauma would be characterised by callus formation, displacement and more variable anatomical positioning. Furthermore, the radiograph (Fig. 3) shows normal bone in the ‘wall’ of the core in the lesion and the trabeculae underlying the lesion are consistent in appearance with the rest of the sinus.

It is possible that such lesions represent an anatomical variant and do not have a pathological origin. However, the constrictions of the horncore in the Chillingham specimen could reflect a metabolic imbalance. Once fused to the frontal bone, horncores develop through appositional growth at the tip and the surface; as growth comes to an end, cortical bone is laid down within the interior (Davis et al. 2011: 2861). In contrast to antlers, horncores undergo active remodelling throughout the animal’s life (Davis et al. 2011: 2861). The fact that ring depressions occur consistently towards the base, suggests that they form towards the end of horncore development, or after the horncore is fully developed: more variable positioning would be expected if they occurred during the active phase of horncore growth, mirroring the presentation of hypoplastic defects in teeth.

Focal resorptive lesions of a different character (sometimes termed “thumbprint depressions”), have been observed in the horncores of domestic (cattle, sheep and, to a lesser extent, goat) and wild (steppe bison) bovids (Albarella 1995; Bartosiewicz 2013: 160-163; Clutton-Brock et al. 1990; Hatting 1975; Keirdorf et al. 2016) (Table 1). In sheep, this condition was originally thought to have been caused by castration; however, their occurrence in ewes ruled out this explanation (Hatting 1975: 346). Instead, these lesions were reinterpreted as a secondary response to “environmental stresses, such as malnutrition, repeated pregnancies and lactations, intensive milking, or ... a combination of these factors” (Albarella 1995, 704). In Late Pleistocene steppe bison (*Bison priscus*), Kierdorf et al. (2016) similarly concluded that they reflected localized bone resorption during periods when demand for minerals exceeds dietary intake, resulting in the mobilisation of calcium and phosphorus from osseous tissues. Circumstantially, the feral status of the Chillingham cattle, might have increased the likelihood of primary or secondary nutritional inadequacies.

Supporting evidence for this interpretation is potentially provided by co-occurring ring and “thumbprint” depressions in three cattle horncores (0.12%) at Witter Place, Chester (Fig. 4), although not at City Road. However, the fact that “thumbprints” and ring depressions are more frequently identified in isolation rather than together (Table 1), could equally indicate that the two pathologies have different aetiologies but occasionally co-occur by chance. Further research is required to establish any potential link.

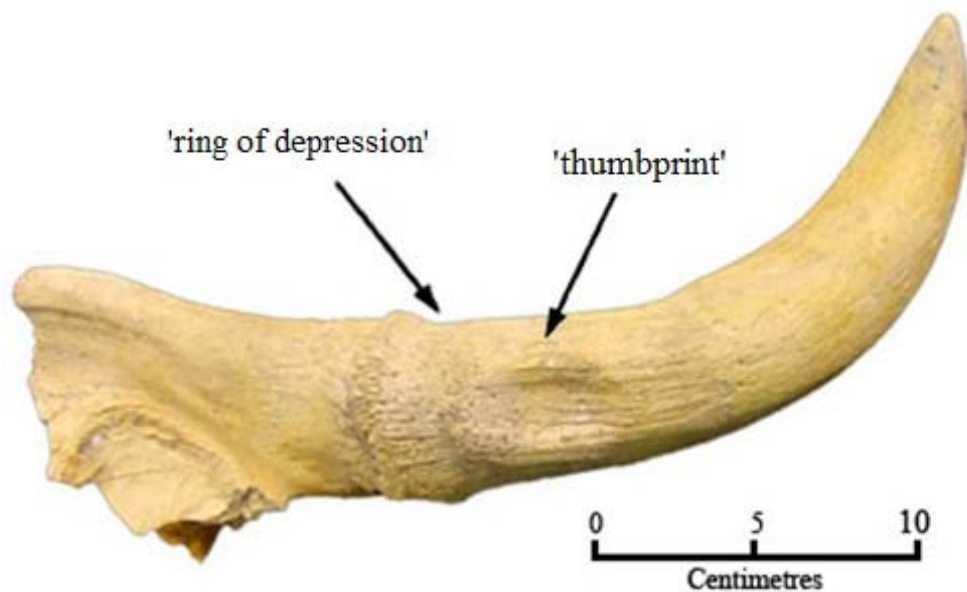


Fig 4: Horncore from Witter Place exhibiting a co-occurring ring and thumbprint depression

### 3 Conclusions

In summary, this discovery casts doubt on the attribution of ring depressions in cattle horncores as conclusive evidence of ‘cord impressions’ resulting from yoking or reining cattle for traction. Drawing upon evidence of horncore depressions in other species, we suggest that they reflect metabolic problems following horn development. Studies of cattle exhibiting ring depressions with detailed life histories and/or dietary stable isotope and histological analyses of archaeological specimens are required to test this hypothesis.

## Acknowledgements

We would like to acknowledge the Chillingham Park estate and in particular, Chris Leland. Thanks also to the College of Arts and Law and the School of History and Cultures at the University of Birmingham who kindly funded the field work at Chillingham. Figures 1 and 2 were taken by Katrien Janin. City Road, Chester, was excavated by L-P Archaeology; Witter Place, Chester was excavated by Earthwork Archaeology. Many thanks to the reviewers and editor, for enhancing the quality of this contribution.

## References

- Albarella, U. 1995. Depressions on sheep horncores. *Journal of Archaeological Science* 22: 699-704.
- Bartosiewicz, L. 2013. *Shuffling Nags, Lambe Ducks: The Archaeology of Animal Disease*. Oxford: Oxbow.
- Bartosiewicz L., Van Neer W. and Lentacker A. 1997. *Draught Cattle: their Osteological Identification and History*. Tervuren: Annalen Koninklijk Museum voor Midden-Afrika, Zoölogische Wetenschappen 281.
- Clutton-Brock, J., Dennis-Bryan, K., Armitage, P.L. and Jewell, P. 1990. Osteology of the Soay sheep. *Bulletin of the British Museum of Natural History (Zoology)* 56: 1-56.
- Davis, E. B., Brakora, K., and Lee, A. H. 2011. Evolution of ruminant headgear: a review. *Proceedings of the Royal Society B: Biological Sciences* 278 :2857-65
- de Cupere B., Lentacker A., Van Neer W., Waelkens M. and Verslype L., 2000. Osteological evidence for the draught exploitation of cattle: first applications of a new methodology. *International Journal of Osteoarchaeology* 10: 254-267.
- Doherty, S., Clarke, K., Poole, K., Roberts, J. and Sykes, N. unpublished. The animal remains from Witter Place, Chester. Unpublished report for Earthwork Archaeology.
- Gomes, R. G., Rafael, L. A., Headley, S. A. and de Almeida Sampaio, A. J. S. 2012. Clinical and histopathological features of horn core carcinoma in a Nellore cow – case report. *Semina: Ciências Agrárias, Londrina* 33: 1931-1936.
- Groot M., 2005. Palaeopathological evidence for draught cattle on a Roman site in the Netherlands, pp. 52-57, in Davies J., Fabiš M., Mainland I., Richards M. and Thomas R. (eds), *Diet and Health in Past Animal Populations: Current Research and Future Directions*. Oxford: Oxbow.
- Hall, S. J. G. 2006. Chillingham Park and its wild white cattle. *Journal of the Royal Agricultural Society of England* 167: 40-48.
- Halstead P. 1985. A study of mandibular teeth from Romano-British contexts at Maxey, pp. 219-224, in Pryor F. and French C. (eds), *Archaeology and Environment in the Lower Welland Valley Vol. 1*. Cambridge: East Anglian Archaeology Report 27.
- Hatting, T. 1975. The influence of castration on sheep horns, pp. 345-351, in Clason, A. T. (ed.), *Archaeozoological Studies*. Amsterdam: Elsevier.
- Higham C. F. W., Kijngam A., Manly B. F. J. and Moore S. J. E. 1981. The bovid third phalanx and prehistoric ploughing. *Journal of Archaeological Science* 8: 353-365.



- Issakidou, V. 2006. Ploughing with cows: Knossos and the Secondary Products Revolution, pp. 95-112, in Serjeantson, D. and Field, D. (eds), *Animals in the Neolithic of Britain and Europe*. Neolithic Studies Group Seminar Papers 7. Oxford: Oxbow Books.
- Johannsen N. N., 2005. Palaeopathology and Neolithic cattle traction: methodological issues and archaeological perspectives, pp. 39-51, in Davies J., Fabiš M., Mainland I., Richards M. and Thomas R. (eds), *Diet and Health in Past Animal Populations: Current Research and Future Directions*. Oxford: Oxbow.
- Johannsen, N. 2006. Draught cattle and the South Scandinavian economies of the 4th millennium BC. *Environmental Archaeology* 11: 35-48.
- Kierdorf, U., Meng, S., and Kahlke, R.-D. 2016. Resorptive depressions on a horncore from a Late Pleistocene (MIS 3) *Bison priscus* (Bovidae, Mammalia) from northeastern Germany. *International Journal of Paleopathology* 15: 76-82.
- Kitchener, A. 1987. Fracture toughness of horns and a reinterpretation of the horning behaviour of bovids. *Journal of Zoology* 213: 621-639.
- Lanyon L. E. and Rubin C. T. 1985. Functional adaptation in skeletal structures, pp. 1-25, in Hildebrand M., Bramble D. M., Liem K. F. and Wake D. B. (eds), *Functional Vertebrate Morphology*. Cambridge, MA: Harvard University Press.
- Milisauskas, S. and Kruk, J. 1991. Utilization of cattle for traction during the later Neolithic of southeastern Poland. *Antiquity* 65: 562-566.
- Onar, V., Kahvecioğlu, K. O., Kostov, D., Arumtak, A., Pazvant, G., Chrószcz and İnce, N. G. 2015. Osteological evidences of Byzantine draught cattle from Theodosius Harbour at Yenikapt, Istanbul. *Mediterranean Archaeology and Archaeometry* 15: 71-80.
- Sherratt, A. G. 1981. Plough and pastoralism: aspects of the secondary products revolution, pp. 261-305, in Hodder, I., Isaac, G. and Hammond, N. (eds), *Pattern of the Past: Studies in Honour of David Clarke*. Cambridge: Cambridge University Press.
- Sykes, N., Wan, V., Robinson, J., Timney, B. and Reynolds, R. unpublished. Horn-cores, horses and hides: the animal remains from City Road, Chester. Unpublished report for L-P Archaeology.
- Thomas, R. 2008. Diachronic trends in lower limb pathologies in later medieval and post-medieval cattle from Britain, pp. 187-201, in Grupe, G., McGlynn, G. and Peters, J. (eds.), *Limping Together Through the Ages: Joint Afflictions and Bone Infections*. Documenta Archaeobiologiae 6. Rahden/Westf.: Verlag Marie Leidorf.
- Visscher, P. M., Smith, D., Hall, S. J. G., Williams, J. A. 2001. A viable herd of genetically uniform cattle. *Nature* 409: 303.