

# Endometrial Polyps and Abnormal Uterine Bleeding (AUB-P): What is the relationship, how are they diagnosed and how are they treated?

Clark, Thomas; Stevenson, Helen

DOI:

[10.1016/j.bpobgyn.2016.09.005](https://doi.org/10.1016/j.bpobgyn.2016.09.005)

License:

Creative Commons: Attribution-NonCommercial-NoDerivs (CC BY-NC-ND)

*Document Version*

Peer reviewed version

*Citation for published version (Harvard):*

Clark, T & Stevenson, H 2016, 'Endometrial Polyps and Abnormal Uterine Bleeding (AUB-P): What is the relationship, how are they diagnosed and how are they treated?', *Best Practice & Research: Clinical Obstetrics & Gynaecology*. <https://doi.org/10.1016/j.bpobgyn.2016.09.005>

[Link to publication on Research at Birmingham portal](#)

## General rights

Unless a licence is specified above, all rights (including copyright and moral rights) in this document are retained by the authors and/or the copyright holders. The express permission of the copyright holder must be obtained for any use of this material other than for purposes permitted by law.

- Users may freely distribute the URL that is used to identify this publication.
- Users may download and/or print one copy of the publication from the University of Birmingham research portal for the purpose of private study or non-commercial research.
- User may use extracts from the document in line with the concept of 'fair dealing' under the Copyright, Designs and Patents Act 1988 (?)
- Users may not further distribute the material nor use it for the purposes of commercial gain.

Where a licence is displayed above, please note the terms and conditions of the licence govern your use of this document.

When citing, please reference the published version.

## Take down policy


While the University of Birmingham exercises care and attention in making items available there are rare occasions when an item has been uploaded in error or has been deemed to be commercially or otherwise sensitive.

If you believe that this is the case for this document, please contact [UBIRA@lists.bham.ac.uk](mailto:UBIRA@lists.bham.ac.uk) providing details and we will remove access to the work immediately and investigate.

# Accepted Manuscript

Endometrial Polyps and Abnormal Uterine Bleeding (AUB-P) – What is the relationship; how are they diagnosed and how are they treated?

T Justin Clark, MB ChB, MD (Hons), FRCOG, Honorary Professor, Helen Stevenson, MB ChB, MRCOG, Teaching Fellow and Specialist Registrar in Obstetrics and Gynaecology



PII: S1521-6934(16)30082-7

DOI: [10.1016/j.bpobgyn.2016.09.005](https://doi.org/10.1016/j.bpobgyn.2016.09.005)

Reference: YBEOG 1641

To appear in: *Best Practice & Research Clinical Obstetrics & Gynaecology*

Received Date: 1 August 2016

Accepted Date: 23 September 2016

Please cite this article as: Clark TJ, Stevenson H, Endometrial Polyps and Abnormal Uterine Bleeding (AUB-P) – What is the relationship; how are they diagnosed and how are they treated?, *Best Practice & Research Clinical Obstetrics & Gynaecology* (2016), doi: 10.1016/j.bpobgyn.2016.09.005.

This is a PDF file of an unedited manuscript that has been accepted for publication. As a service to our customers we are providing this early version of the manuscript. The manuscript will undergo copyediting, typesetting, and review of the resulting proof before it is published in its final form. Please note that during the production process errors may be discovered which could affect the content, and all legal disclaimers that apply to the journal pertain.

## **Endometrial Polyps and Abnormal Uterine Bleeding (AUB-P) – What is the relationship; how are they diagnosed and how are they treated?**

T Justin Clark<sup>a,b</sup> MB ChB, MD (Hons), FRCOG and Helen Stevenson MB ChB, MRCOG<sup>c</sup>

- a Consultant Gynaecologists, Birmingham Women's Hospital NHS Foundation Trust, Edgbaston, Birmingham, B15 2TG, UK.
- b Honorary Professor, School of Clinical and Experimental Medicine, College of Medical and Dental Sciences; University of Birmingham, Birmingham, B15 2TT, UK
- c Teaching Fellow and Specialist Registrar in Obstetrics and Gynaecology, Birmingham Women's Hospital NHS Foundation Trust, Edgbaston, Birmingham, B15 2TG, UK.

### **Corresponding author**

Professor T. Justin Clark, Birmingham Women's Hospital NHS Foundation Trust, Edgbaston, Birmingham, B15 2TG, UK.

Email: [t.j.clark@doctors.org.uk](mailto:t.j.clark@doctors.org.uk)

Fax 00441216272667

Phone: 00441216074712

### **Word count**

**6755 words**

**Abstract**

The diagnosis and treatment of endometrial polyps will be familiar to most gynaecologists. However, the aetiology and natural history of these focal intrauterine lesions is far from clear. This lack of clarity is also true as regards their clinical significance; whilst endometrial polyps are highly prevalent in all types of abnormal uterine bleeding (AUB) they are also commonly found in women without AUB. These controversies will be discussed along with current thoughts on the diagnosis and treatment of endometrial polyps. Criteria for diagnosis of uterine polyps vary according to the test used, but optimal testing is not yet solidified. Recent data from randomised trials evaluating new and established surgical technologies as well as comparing treatment protocols and settings will be examined.

**Key words**

Polypectomy; outpatient hysteroscopy; office hysteroscopy; abnormal uterine bleeding

## **[A] Introduction**

### **[A] Relationship of endometrial polyps to abnormal uterine bleeding**

#### **[B] Definition**

Uterine polyps are focal endometrial outgrowths that can occur anywhere within the uterine cavity. They contain a variable amount of glands, stroma and blood vessels, the relative amounts of which influence their visual appearance at hysteroscopy. Polyps may be soft and cystic or firm and fibrous; they may be pedunculated or sessile, single or multiple, and vary in size from small – with minimal uterine cavity distortion – to large, filling the whole cavity (Figure 1) [1].

Most endometrial polyps are diagnosed on imaging via transvaginal pelvic ultrasound (TVS) or hysteroscopy and confirmation is provided by histological examination of the removed specimen. Thus, in clinical practice the features that define an endometrial polyp will relate to the diagnostic modality, although agreed, standardised definitions are lacking (Table 1).

#### **[B] Aetiology**

The underlying mechanism of uterine polyp formation remains unclear but is believed to be multifactorial [2]. Uterine polyps are thought to start as focal areas of stromal and glandular overgrowth within the endometrium [3, 83]. The effect of hormones on polyp formation is unclear and may differ according to menopausal status. In premenopausal women, a decrease in oestrogen and progesterone receptors within polyp stromal cells may make polyps less sensitive to cyclic hormonal changes [4, 84]. Increased cell longevity may also play a role in the genesis of polyps as a result of inhibition of apoptosis [5] and altered gene expression [6, 7].

#### **[B] Epidemiology**

#### **[C] Prevalence**

The prevalence of uterine polyps in a general adult female population without abnormal uterine bleeding (AUB) is generally estimated to be around 10-15% [8]. Uterine polyps were detected incidentally during TVS in 12% of premenopausal women and in 6–11% of infertile women without AUB [9] [10]. In asymptomatic postmenopausal women undergoing TVS a polyp prevalence of 13% was found [11] and 16% [12, 13] during hysteroscopy. Risk factors for uterine polyp development are thought to include obesity, late menopause and the use of the partial oestrogen agonist tamoxifen [11, 14, 15]. The role of hormone replacement therapy (HRT) on polyp formation is unclear, with some studies supporting an association [11, 13] and others not [16, 17].

Whilst uterine polyps may be an incidental finding, they appear to be more prevalent in women undergoing investigation with high-resolution pelvic ultrasound or hysteroscopy for AUB. The

prevalence of polyps found associated with AUB varies according to the criteria used to define a polyp, the diagnostic test used, and the type of population studied. In general, the prevalence of endometrial polyps is considered to be between 20% and 30% [16,18,19]. Uterine polyps affect pre- and postmenopausal women with AUB 46 and indeed the prevalence may be increased after the menopause [11].

The high frequency in which uterine polyps are discovered in women of reproductive age and the likely causative association between uterine polyps and AUB has been recognised in the International Federation of Gynecology and Obstetrics (FIGO) classification system for causes of AUB during the reproductive years. This nomenclature is based upon the acronym 'PALM-COEIN' with the 'P' denoting a 'polyp', i.e. describing AUB associated with the presence of uterine polyps (AUB-P) [20].

### **[C] Natural history**

Most uterine polyps will persist if left untreated although small polyps may spontaneously regress [21]. In a small cases of asymptomatic premenopausal women 27% of polyps naturally regressed after one year of follow-up be smaller, in keeping with an earlier case series [22].

The majority of uterine polyps are benign. Estimates of the prevalence of hyperplasia and cancer vary across study populations. A systematic review of observational studies reported endometrial hyperplasia (EH) without atypia rates between 0.2–23.8% in polyps [23]. The prevalence of premalignant atypical endometrial hyperplasia (AEH) appears to be lower with estimates in primary studies ranging from between 1% and 3% [24, 25, 26, 27].

Endometrial polyp cancer prevalence has been reported to range from 0.5–3% [28, 29, 30, 31, 32, 24, 25, 26].

Risk factors for malignancy within uterine polyps include abnormal uterine bleeding, increasing age, postmenopausal status, obesity, diabetes [24, 25, 26] an increased polyp size [26, 27] and tamoxifen [14, 33]. Another systematic review reported the prevalence of endometrial hyperplasia or cancer within polyps in women with symptomatic bleeding as 4.2% (195/4697) compared with 2.2% (85/3941) for those without bleeding (relative risk (RR) 1.97; 95% confidence interval (CI) 1.24 to 3.14). The risk of pre-malignancy or malignancy within a uterine polyp was higher in symptomatic postmenopausal women (5.4%, 214/3946) compared with 1.7% (68/3997) in reproductive-aged women (RR 3.86, 95% CI 2.92 to 5.11).

### **[B] Abnormal uterine bleeding**

The high prevalence of uterine polyps in women with all forms of AUB, namely HMB, IMB and PMB, has become increasingly apparent with the widespread adoption of high-resolution pelvic ultrasound and greater access to outpatient hysteroscopy. In addition to this observation of high prevalence in women with AUB, causality has also been inferred from the effect of removing polyps on bleeding symptoms. Collated evidence from systematic reviews have found that alleviation or improvement in AUB symptoms is generally observed following polypectomy (range 75–100%) [34]

at follow-up intervals of between 2 and 52 months. However, these studies were generally uncontrolled small series. Moreover, reliable stratification of treatment outcome according to type of abnormal bleeding was not possible in these reviews. Recent RCTs have provided additional data on treatment outcomes in AUB following polypectomy and this is discussed in more detail in the treatment section of this chapter.

The mechanism by which polyps arising from the endometrium precipitate these different forms of AUB remains uncertain and may be linked to the equally unclear underlying aetiology of polyp formation. Thus, factors such as altered responses to oestrogen and progesterone compared to the background endometrium, inflammatory changes and disturbed angiogenesis may be involved but these possible explanations remain speculative. Attempts are being made to produce a practical and reproducible sub-categorisation system of the AUB-P category within the PALM COEIN nomenclature [20]. By developing such a system based upon features such as the number, size, shape, location, composition and vascularity of polyps it is hoped that questions pertaining to the significance of uterine polyps found in association with particular AUB presentations may be more readily answered.

## **[A] Diagnosis of endometrial polyps in abnormal uterine bleeding**

In women with abnormal uterine bleeding in whom endometrial polyps are suspected there are three main modes of investigation.

### **[B] Ultrasound**

Initial assessment of endometrial disease is often via radiological imaging. Ultrasound (USS) is usually the first imaging modality and has the advantage of providing information on the size of the uterine cavity and other pathology including leiomyomas. It is non-invasive and therefore generally acceptable to the majority of patients with minimal discomfort. With plain transvaginal ultrasound (TVS) a polyp appears as endometrial thickening or with the more typical appearance of a hyperechoic lesion within the uterine lumen with a regular contour and surrounded by a thin hyperechoic halo [35]. Transvaginal ultrasound is more accurate when performed in the proliferative phase of the menstrual cycle [36]. The accuracy of TVS in diagnosing uterine polyps varies across test accuracy studies with accuracy estimates ranging from sensitivities of 19-96%, specificities between 53-100% and positive predictive values of between 75 and 100% and negative predictive values of 87-97% when compared to hysteroscopy and guided biopsy [37]. In general, TVS appears to have a good degree of accuracy when performed with high resolution equipment by proficient practitioners. Polyp size should be assessed at the time of US as this can provide vital information, useful in aiding management. An increase in the diameter of the polyp appears to correlate with risk of malignancy [30] with smaller polyps being more likely to resolve spontaneously [22].

Further enhancement with Colour flow Doppler or Power Doppler can be used to improve diagnostic accuracy when using TVS to assess the endometrial cavity. Colour flow Doppler is useful in demonstrating the single feeding vessel seen with endometrial polyps and Power Doppler of the vascularity has been shown to improve diagnostic accuracy when looking at endometrial polyps in both asymptomatic and symptomatic women [38]. There is, however limited evidence that either

power Doppler or colour flow Doppler increases the diagnosis of malignancy or hyperplasia within polyps and therefore histological diagnosis is still necessary following detection via TVS. Power Doppler has been reported to be more accurate than colour flow for demonstrating vascular networks in one study looking at postmenopausal women with abnormal bleeding and thickened endometrium on baseline US [38].

The addition of intra-uterine contrast via saline infusion sonography (SIS) or gel installation sonography (GIS) may be used to improve diagnostic accuracy compared to TVS alone. With SIS the fluid allows better contrast between the endometrial cavity allowing for delineation of the base or stalk of the polyp and improving detection of smaller polyps which may have been missed by TVS alone [39]. In contrast to SIS, there is currently limited data on the accuracy of GIS in diagnosing uterine polyps.

When comparing SIS with hysteroscopy, SIS had a sensitivity of 58-100%, specificity 35-100%, PPV 70-100% and NPV 83-100% [36]. A systematic accuracy review using hysteroscopy with or without biopsy or hysterectomy as reference standards found that the accuracy of SIS in the diagnosis of endometrial polyps was lower compared with diagnosing other uterine cavity abnormalities such as submucous fibroids. The pooled sensitivity was 0.86 (95% CI 0.81 to 0.91) and the pooled specificity was 0.81 (95% CI 0.72 to 0.88) and the likelihood ratios (LRs) were respectively 5.23 (95% CI 3.98 to 6.90) and 0.12 (95% CI 0.08 to 0.17) consistent with a moderately accurate test for detecting and excluding polyps [40]. Saline infusion sonography simultaneously allows for assessment of other pelvic structures including the adnexa and myometrium as well as the uterine cavity and tubal patency and therefore provides a useful adjunct to TVS especially when assessing patient's pre-operatively to decide on the procedure most likely to benefit the patient. The main disadvantage of SIS and GIS is the increased level of operator training needed compared to TVUS alone as well as patient discomfort during the longer examination.

3D USS has been used in assessment of the endometrium but showed limited improvement in diagnosis compared to 2D TVS [41] although this is slightly improved with the addition of intrauterine contrast. One study reported high accuracy of 3D USS in diagnosing uterine polyps with a derived sensitivity of 100%, specificity 99%, PPV 99% and NPV 100% compared to hysteroscopy and guided biopsy [36].

## **[B] Hysteroscopy**

The gold standard investigation for diagnosis of endometrial polyps is hysteroscopy and guided biopsy. Hysteroscopy has the advantage of allowing the practitioner to directly visualise the endometrium and remove any polyps at the same time for histological diagnosis meaning the patient does not have to return for treatment. It also gives the advantage of detecting other endometrial pathology such as submucous fibroids which may also be treated at the same time or assessed for further treatment at a later operation. The overall complication rate for hysteroscopy is small but increased compared to USS imaging alone with the overall risk of serious complications 2 in 1000 women [42]. A systematic review comparing hysteroscopy with hysteroscopically directed biopsy or hysterectomy [43] showed a high degree of accuracy with a pooled sensitivity of 0.94 (95% CI 0.92–0.96) and specificity of 0.92 (95% CI 0.91–0.94). The corresponding positive and negative likelihood ratios were 12.9 (95% CI 8.0–20.9) and 0.09 (95% CI 0.06–0.14) respectively. The ability to



exclude a polyp was higher in women after the menopause which may reflect easier visual discrimination of a focal endometrial lesion from the thin inactive background endometrium (premenopausal women LR+ 33.5, 95% CI 8.2–136.0 and LR- 0.16, 95% CI 0.09–0.28; postmenopausal women LR+ 12.0 (95% CI 4.0–35.8) and LR- 0.04 (95% CI 0.01–0.26)

Whilst hysteroscopy has high accuracy for the diagnosis of endometrial polyps, the test involves a subjective assessment of the size and features of the polyp and directed biopsy should therefore be performed, even if the polyp appears benign and is not causing symptoms. Diagnostic hysteroscopy missed endometrial hyperplasia in 0.9% of patients in one large RCT and had a lower sensitivity and positive predictive value than hysteroscopy with directed biopsy [44]. A large systematic review and meta-analysis of hysteroscopy has however demonstrated the high accuracy of the test in malignant and pre-malignant endometrial disease although this did not specifically relate to cancer or hyperplasia within a uterine polyp [45].

Hysteroscopy is frequently performed in the outpatient setting with greater patient satisfaction with the outpatient procedure and similarly high success rates of 92-6% [46]. Care should be sought over the equipment used in outpatient hysteroscopy. Flexible hysteroscopy may be used owing to the reduction in patient discomfort over the use of rigid scopes however 2 prospective studies have revealed reduced accuracy when assessing for endometrial polyps with flexible hysteroscopy giving a sensitivity of 74% and specificity of 90% [47].

### **[B] Endometrial biopsy**

Pelvic examination of women with abnormal uterine bleeding may provide an opportunity for blind sampling of the endometrium using miniature aspiration devices most being based upon the Pipelle® biopsy prototype or traditional dilatation and curettage (D&C). These blind techniques fail to sample a significant proportion of the endometrial cavity and so not surprisingly for focal pathologies like uterine polyps, blind biopsy has low accuracy compared with hysteroscopy and guided biopsy [48, 49]. This technique will frequently miss polyps particularly if small or pedunculated and makes histological diagnosis more difficult due to the tissue fragmentation. Histology is also unable to confirm the polyp has been removed at the base and therefore blind biopsy should not be used as a diagnostic test when investigating for endometrial polyps.

## **[A] Treatment of endometrial polyps in abnormal uterine bleeding**

### **[B] Expectant management**

The surgical treatment of uterine polyps is excision or 'polypectomy'. Uterine polypectomy is one of the commonest procedures in contemporary gynaecological practice. Surgical removal aims to treat associated symptoms such as AUB or subfertility and also to obtain tissue for histological examination. A UK national survey [50] and two subsequent Dutch surveys [69, 70] confirmed that the vast majority of gynaecologists advocated surgical removal of polyps from the uterus after diagnosis. However, the need to universally remove uterine polyps may be questioned in light of the observations that polyps are found incidentally in around 5–15% of women [11, 9, 10, 12], most are

benign [53, 54] and some may regress spontaneously [22, 21]. Two randomised controlled trials (RCTs) have addressed this issue, randomising women with AUB and uterine polyps to expectant management or surgical removal [53, 54]. One of these RCTs randomised 150 pre-menopausal women with uterine polyps, of which 60% had AUB symptoms. Overall, no reduction in periodic blood loss was demonstrated at 6 months following surgical excision but IMB symptoms were significantly improved [54].

Another RCT [56] attempted to determine the significance of uterine polyps on the risk of recurrent post-menopausal bleeding (PMB) by randomising women with PMB to either polypectomy versus expectant management. However, the lack of equipoise of both patients and their clinician's hindered recruitment so that the trial could not be completed. The authors then redesigned their RCT to overcome the observed reluctance to leave a hysteroscopically detected uterine polyp in situ [57]. Women with PMB and a thickened endometrium on TVS and a subsequently benign endometrial biopsy were randomised to undergo further testing with a hysteroscopy or no further investigation. Women allocated hysteroscopy who were found to have a uterine polyp had it duly removed. The same polyp prevalence was assumed in the expectant group and so the impact of polypectomy on recurrent PMB at 12 months could be assessed. Nearly one in five women experienced recurrent PMB over the year but no differences in prevalence of recurrent PMB were seen between groups. Thus expectant management on symptomatic grounds seems a viable option as opposed to hysteroscopic polypectomy. The RCT was however underpowered. Of great interest was the finding that there was a 6% incidence of atypical hyperplasia or cancer in the hysteroscopically removed polyps. Thus, hysteroscopic polypectomy appears to be indicated to aid diagnosis of serious endometrial disease but not to alleviate bleeding symptoms.

### **[B] Medical management**

Evidence supporting the use of medical treatment of uterine polyps is lacking although hormonal treatments are widely used to treat menstrual complaints of which some will be associated with uterine polyps. Pre-treatment with gonadotrophin-releasing hormone analogues ('GnRH-a's) prior to hysteroscopic resection of focal pathologies in premenopausal women [57] has been reported but the costs and morbidity of this intervention is unjustifiable given the relative simplicity and success of removing uterine polyps as opposed to more technically challenging submucosal fibroids. Rather than using medical therapies to directly treat polyps, medical treatments have been examined to prevent their formation. For example the use of the levonorgestrel-releasing intrauterine system (LNG-IUS) in women taking tamoxifen may reduce the incidence of endometrial polyps [60, 61].

### **[B] Surgical management**

The surgical removal of intrauterine polyps can be achieved blindly or under direct hysteroscopic vision.

### **[C] Blind polypectomy**

Blind removal of uterine polyps utilising 'dilatation and curettage' (D&C) under general anaesthetic or avulsion with polyp forceps has yet to be fully consigned to its rightful place in the history books.

National surveys from the UK and Netherlands [50, 51, 52] albeit from a decade or so ago, still indicate that such practices are common place. The technique involves wide dilatation of the cervix and the use of standard surgical polypectomy forceps to explore the uterine cavity. These approaches can be associated with potential uterine trauma and visceral trauma [60]. Incomplete removal of polyps is also well recognised [62, 63, 64]. Most gynaecologists would perform a hysteroscopy beforehand to locate the polyp to direct blind avulsion of the lesion followed by curettage [50].

### **[C] Hysteroscopic uterine polypectomy**

Advances in hysteroscopic technology have enabled polyps to be removed under direct vision using fine mechanical and electrosurgical equipment which are passed down a 5- or 7-French working channel of a rigid, continuous flow operating hysteroscope [8, 63, 66, 34] and more recently the introduction of bespoke tissue removal systems [67, 68]. All these techniques require hysteroscopic visualisation within the uterine cavity, excision of the polyp tissue from the uterine wall and retrieval from the uterine cavity. Traditional approaches to inserting the hysteroscope have entailed the use of a vaginal speculum, cervical instrumentation and local anaesthesia. However, vaginoscopic approaches are increasingly being adopted avoiding the use of vaginal instrumentation thereby minimising pain and allowing the operator greater degrees of movement externally to facilitate manipulations within the uterine cavity during the surgical procedure [69].

#### ***[D] Mechanical***

Uterine polyps can be removed by excision or avulsion using a variety of fine mechanical instruments in isolation or combination. Such ancillary instruments include reusable scissors, biopsy cups, forceps and disposable polyp snares (Figure 2). The safety, feasibility and efficiency of such approaches have been well reported [8, 64, 65, 34]. However, fragility of the instruments preclude the excision or avulsion of large or fibrous polyps and bleeding may occur [69]. The limited degree of movement of these instruments can also limit feasibility. The diameter of the cervical canal relative to the excised polyp creates challenges to removing pathology as polyp tissue may slip from the small diameter grasping forceps when attempting retrieval down the endo-cervical canal. In such circumstances the operator will have to consider blind dilatation of the cervix to allow further attempts at hysteroscopic retrieval with grasping forceps or the use of polyp snares. Recourse to blind retrieval of a detached polyp using standard polyps forceps should not be attempted routinely. In the authors opinion, blind retrieval in this way should only be attempted where histological examination of a suspicious looking polyps is considered necessary because the risks of uterine and intra-abdominal trauma are not insignificant especially if the procedure is to be carried out under general anaesthesia [1]. In general, hysteroscopic polypectomy using small diameter mechanical instruments should be limited to smaller, glandular polyps.

#### ***[D] Electrosurgical***

The application of electricity has enhanced the cutting potential of hysteroscopic instruments such that the limitations of fine mechanical technologies are overcome, namely the removal of larger and more fibrous polyps. Large-diameter hysteroscopic resectoscopes can be used under general

anaesthesia or conscious sedation. The resecting loop can be used to remove the polyp in strips with repeated passes of the cutting loop or en bloc by cutting the base of the polyp where it adjoins the uterine side wall. However, whilst the use of formal resectoscopes is quick and effective, a greater degree of specialised hysteroscopic skills are required [70, 71] cervical and uterine trauma can result from the need for blind cervical dilatation along with complications arising from fluid overload and inadvertent electro-surgical injury [72]. Moreover, given the fully intra-cavity position and generally soft nature of most polyps, the resectoscope is a somewhat 'overpowered' technology and in the authors opinion these technologies are better employed for the removal of firmer and more deeply sited submucous fibroids. The use of a 5.3mm (16 Fr gauge) mini-resectoscope has been described for use in the inpatient and outpatient setting but this technology has not been widely adopted [73].

Advances in hysteroscopic electro-surgical technologies include improvement in visualisation and image quality, the development of safer bipolar systems and miniaturisation of equipment such that uterine trauma can be minimised and procedures performed without the need for general anaesthesia or sedation. A miniature bipolar electro-surgical system (Figure 3) has been developed (Versapoint, Gynecare, Ethicon, Somerville, NJ, USA) to cut away polyps and the safety, acceptability and feasibility of this approach has been reported [74, 75, 76]. The Versapoint® bipolar electrodes are single use but reusable electrodes are available e.g. the bipolar dissection electrode (Karl Storz, Tuttlingen, Germany). However, as with small diameter mechanical instruments, retrieval of larger or fibrous tissue specimens from the uterine cavity, especially where the diameter of the endo-cervical canal is restricted, remains problematic. Mechanical instruments such as hysteroscopic graspers, biopsy cups and snares are required to retrieve the specimen with the limitations as outlined in the preceding section. In general, the authors favour the efficient en-bloc electro-surgical removal of a polyp by detaching it directly from its base but where larger or fibrous polyps are identified, then removal piecemeal by cutting several strips of tissue may be preferable because difficulty with retrieval from the uterine cavity can be anticipated. However, such an approach is more cumbersome and usually results in a longer intrauterine operating time which can be disadvantageous especially in an outpatient setting [8].

Disposable hysteroscopic polyp snares are available (Cook Medical, Bloomington, USA). The snare is passed down the operating channel of the hysteroscope and opened to ensnare the polyp which is detached by the application of monopolar energy and then removed by withdrawing the entire hysteroscopic system from the uterine cavity [65]. The ease at which polyps can be ensnared depends upon their location and size. A non-conducting medium such as glycine or sorbitol is required. Snares can also be used without activating current in order to retrieve previously detached polyps (see above).

The main limitations of using miniature electro-surgical cutting instruments include potential thermal complications arising from uterine perforation and the inability to retrieve detached tissue specimens from the uterine cavity down the relatively narrow endo-cervical canal. Recognition of these problems and a desire to overcome them has led to the development of hysteroscopic tissue removal systems. (TRUCLEAR™, Smith & Nephew, Andover, MA, USA), Myosure (Hologic, Marlborough, MA, USA) and the IBS® - Integrated Bigatti Shaver (Karl Storz, Tuttlingen, USA), which allow simultaneous tissue cutting and extraction. 813299,100 More recently the SYMPHION™ (Boston Scientific, Natick, MA) has been produced which combines a tissue removal system with bipolar radiofrequency energy.

**[D] Tissue removal systems**

Hysteroscopic tissue removal systems have been developed to remove focal pathologies such as polyps and submucous fibroids without the need for electrical energy [77]. Tissue removal systems allow simultaneous mechanical cutting and tissue aspiration allowing clear views as debris from uterine polyps, fragmented endometrium or in the case of SMFs 'fibroid chips' are prevented. The TRUCLEAR™ and MyoSure™ tissue removal systems consist of a bespoke 0° hysteroscope (IBS® 6° distal lens) with an operating channel through which a disposable cutting hand piece attached to external suction tubing is passed (Figure 4). This hand piece comprises of two rotating hollow metal tubes each with a small distal window with serrated edges or a rotary blade edges through which the tissue is cut and retrieved. The removed tissue is sucked through the device and trapped in a tissue collector within the external suction housing. The control unit consist of a generator providing the electrical energy to rotate the mechanical tissue removal system and a digital display.

Currently available tissue removal systems come in a variety of specifications as regards their size and cutting mechanism. In general the smaller devices are suitable for polyps whereas the larger systems are designed for removing firmer fibroid tissue. The TRUCLEAR™ system was the first to be developed and marketed; the TRUCLEAR™ 5C system provides continuous flow if the outer irrigating sheath is used. The outer diameter is 5.7mm, a diameter that avoids the need for routine cervical dilatation making it suitable for outpatient based procedures and this can be reduced to 5mm if the outer sheath is dispensed with (the suction down the hollow tubes providing irrigation). The TRUCLEAR™ 8.0 set is 9mm in outer diameter containing a larger optic and working channel to house the rotary blade. The MyoSure™ system utilises hysteroscopes of 6 mm and 7 mm according to the particular cutting system used. The IBS® system uses an 8mm operating hysteroscope

The techniques are simple, essentially approximating the cutting aperture of the hand piece to the polyp and ensuring cutting and aspiration of tissue continues without interruption via small, gentle manipulations of the hysteroscope and hand piece. To prevent blood and debris obscuring the visual field it is important to keep the device activated to ensure these products will be sucked into the window. The technique is much simpler than traditional electrosurgical resection of fibroids or polyps such that any learning curve for trainees is negligible [66].

**[B] Evidence for polypectomy in treating abnormal uterine bleeding**

Two systematic reviews support the notion that removing uterine polyps is effective at improving symptoms of AUB. However, the quality of the research was generally poor consisting mainly of uncontrolled observational series with heterogeneous populations, length of follow up and outcome assessment, such that it remained unclear whether menopausal status or the type of AUB e.g. IMB or HMB influenced the treatment outcome. Large RCTs were recommended to compare conventional polypectomy with conservative management as well as traditional inpatient with novel outpatient approaches to polyp treatment to identify best practice before opinion is solidified [34, 23, 36]. Since these reviews were published, three RCTs have been performed and published [54, 78, 56].

Two of these RCTs support the role of polypectomy for treating AUB found in association with AUB [54, 78]. The outpatient polyp treatment (OPT) trial [78] was an RCT comparing the effectiveness of inpatient polypectomy under general anaesthesia for the treatment of AUB (HMB, IMB, PMB, AUB on HRT / Tamoxifen) with outpatient treatment in conscious women with or without the use of local anaesthesia. Blind and hysteroscopic approaches to surgery were allowed and the latter included mechanical or electrosurgical energy. The majority of women were alleviated of their AUB symptoms at six months (73% (166/228) of women who received outpatient treatment and 80% (168/211) who received inpatient treatment) and the treatment effects were maintained at 12 and 24 months. There was no evidence that successful resolution of symptoms varied by primary bleeding complaint (i.e. HMB, IMB, PMB), or polyp type and location. Significant improvements in generic and disease specific quality of life were also observed after polypectomy. However, this RCT had no placebo group because it was designed to look at differences in AUB outcomes for polypectomy according to treatment setting rather than the more fundamental question pertaining to the effectiveness of uterine polypectomy.

However, two RCTs did compare uterine polypectomy with expectant management [54, 56]. One RCT evaluated transcervical resection of endometrial polyps against a policy of observation alone in 150 premenopausal women of which only 60% had AUB symptoms. Overall, no reduction in periodic blood loss as assessed using pictorial blood assessment charts (PBACs) was demonstrated at 6 months' follow-up, but IMB and vaginal discharge symptoms were significantly improved (ongoing IMB symptoms in 7/75 treated patients (9.3%) vs. 28/75 control patients (37.3%);  $p < 0.001$ ). [54] The other RCT was restricted to postmenopausal women with bleeding. The original design was similar to the aforementioned RCT in pre-menopausal women i.e. a simple polypectomy versus expectant management but recruitment was not possible because of lack of equipoise in both patients and their clinicians [55]. The redesigned RCT simply randomised women with benign disease after diagnostic work up with TVS and EB between hysteroscopy (with polypectomy if a polyp was detected) and expectant management as described earlier [56]. The same polyp prevalence was assumed in the expectant group and so the impact of polypectomy on recurrent PMB at 12 months could be assessed.

Hysteroscopic polypectomy did not reduce the likelihood of recurrent PMB so treatment on symptomatic grounds appears to lack justification, although the lack of power in the RCT cannot exclude polypectomy as an effective treatment for AUB. However, a 6% incidence of serious endometrial disease (atypical hyperplasia or cancer) was detected in the removed polyps. Thus hysteroscopic polypectomy is indicated to aid diagnosis of serious endometrial disease but not to alleviate bleeding symptoms. These findings raise interesting questions about the aetiology of PMB and the validity of recommendations on the diagnostic work up of PMB [80] as these are based upon a probable overinflated estimate of the accuracy of outpatient endometrial biopsy (blind dilatation and curettage being the usual reference standard rather than hysteroscopically directed biopsy).

Thus, it remains unclear as to the best policy for managing uterine polyps diagnosed during investigations for AUB. The majority of women appear to have their symptoms alleviated after polypectomy but it is uncertain whether the removal of the lesion accounts for this desirable outcome. However, the hysteroscopic removal of polyps appears to be safe, with a low complication rate noted in all three RCTs [54, 78, 56] (the OPT trial recorded four uterine perforations (4/233, 2%) with one associated bowel injury following blind, as opposed to hysteroscopically directed removal



techniques in inpatient women under general anaesthesia; no such complications were noted in the outpatient group [78] and in symptomatic postmenopausal women removal seems important to exclude pre-malignant and malignant disease.

### **[B] Treatment setting**

Uterine polypectomy could only be conducted in the past using blind interventions, namely D&C and avulsion with forceps. To introduce such instruments required dilatation of the cervix and manipulation within the uterine cavity, manoeuvres that necessitated the use of general anaesthesia. Technological advances have facilitated polyp removal under direct hysteroscopic vision using small diameter endoscopes. The increased precision of surgery and avoidance of the need for routine substantial dilatation of the cervix has meant this common gynaecological procedure can be conducted in the outpatient setting and without general anaesthesia. Indeed often no local anaesthesia is required especially when using hysteroscopic systems under 6mm in outer diameter and adopting a vaginoscopic approach [68]. Direct cervical injection or paracervical injection of local anaesthesia is used where cervical dilatation is required. Intrauterine instillation or injection of local anaesthesia has been the subject of recent studies but there is no evidence to support its use nor the use of conscious sedation for uterine polypectomy [80, 81]. Many studies have reported the feasibility including acceptability of small diameter mechanical and electrosurgical techniques for outpatient polypectomy. However, these techniques have not been widely adopted despite such studies. This may relate to a lack of skills, access to contemporary endoscopic technologies, embedded clinical prejudices or a concern that outpatient procedures being limited by patient factors may result in poorer clinical outcomes such as resolution of AUB. A recent large, multicentre RCT based in the UK involving more than 30 outpatient hysteroscopy units has been able to answer the latter question regarding the relative effectiveness of outpatient versus inpatient uterine polypectomy [78].

### **[C] Evidence for outpatient treatment**

The results of the Outpatient Polyp Treatment trial (OPT trial) showed that outpatient polypectomy was not inferior to inpatient polypectomy for the successful alleviation of uterine bleeding associated with uterine polyps. At six months 73% (166/228) of women who received outpatient treatment and 80% (168/211) who received inpatient treatment were successfully treated, and the treatment effects were maintained at 12 and 24 months. There was no evidence that successful resolution of symptoms varied by primary bleeding complaint (i.e. HMB, IMB, PMB), polyp type (fibrous or glandular) and location (fundal vs. non-fundal). An equivalent and significant improvement in generic and condition specific quality of life was seen after polypectomy. Importantly there were fewer serious complications in the outpatient group; no uterine perforation compared with four in the inpatient group (including one bowel injury). However the study was too small to categorically answer the question as to the safest treatment setting and operative techniques employed [78].

A patient preference study (cohort study) was run along alongside the RCT side for women with a strong treatment setting preference precluding randomisation [1] 81% of the 399 women in this

study expressed a preference for outpatient treatment and a formal qualitative study utilising semi-structured interviews and thematic analysis confirmed that the immediacy of treatment, avoidance of hospital admission, time off work and overall convenience of an outpatient procedure was highly valued [1]. However, outpatient polypectomy was associated with more technical failures (18% versus 7%), increased postoperative pain, and reduced acceptability to patients. The differences in post-operative pain scores and acceptability were marginal and unlikely to be of clinical significance. Average pain scores during the outpatient procedure were of moderate intensity but low postoperatively, and our qualitative research suggested that women believed that the discomfort of outpatient treatment was outweighed by convenience. Moreover, the differences may reflect the shorter interval between intervention and pain assessment before leaving the outpatient clinic. The clinical importance of differences in acceptability should be interpreted in light of the high overall levels of patient acceptability and the convenience of outpatient treatment (98% of women found the procedure acceptable in both outpatient and inpatient groups).

However, what about technical success? Technical success was defined as complete excision (detachment) and retrieval of the polyp tissue from the uterine cavity. The fact that failure to completely remove polyps was higher in conscious women may reflect the limitations of miniature endoscopic equipment and patient tolerability. However, tissue removal systems (TRS) were unavailable at the time of recruitment to the study (2008-2011). Whilst the OPT trial utilised variety of polypectomy techniques (blind, hysteroscopic (mechanical or electrosurgical), the absence of TRS is likely to be clinically important [78]. This is because the MERT trial comparing electrosurgery using Versapoint compared with TRS using the TRUCLEAR system, showed a comparable failure rate (49/59; 17%) for miniature Versapoint bipolar electrosurgery compared with that seen in the outpatient arm of the OPT trial (67). However, the failure rate in the TRUCLEAR group was substantially lower (1/62, 2%). Thus, ongoing technological advances and refinement of treatment protocols are improving feasibility. Moreover, outpatient hysteroscopy clinics have become common place but the ability to effect treatments rather than simple diagnostic procedures is less well advanced. Practitioners may require additional training to become competent in therapeutic outpatient procedures. However, proficiency should be quickly acquired given the familiarity of diagnostic outpatient hysteroscopy and the relative simplicity of uterine polypectomy.

The available evidence for effectiveness, feasibility and acceptability of outpatient polypectomy for AUB at worst supports equivalence with conventional inpatient polypectomy under general anaesthesia. Thus, the only obstacle to widespread adoption of the outpatient setting is economics namely the relative cost-effectiveness of outpatient versus inpatient treatment. The inflated cost of miniaturised technologically advanced equipment required for most outpatient procedures may offset the efficiency of outpatient polypectomy even when it is performed immediately following diagnosis at OPH – the ‘see and treat’ approach. To answer this question a formal economic evaluation was carried out alongside the multi-centre, pragmatic, non-inferiority, randomised controlled Outpatient Polyp Treatment (OPT) trial [82]. The results showed that inpatient treatment was slightly more effective but substantially more expensive than outpatient treatment. Incremental cost-effectiveness ratios at 6 months revealed that it cost an additional £9421 per successfully treated patient in the inpatient group and £1,099,167 per additional quality of life year (QALY) gained, when compared with outpatient treatment. At 12 months, these costs were £22,293 per additional effectively treated patient and £445,867 per additional QALY gained, respectively. Thus,



outpatient treatment of uterine polyps associated with AUB appears to be more cost-effective than inpatient treatment at willingness-to-pay thresholds acceptable to the NHS.

ACCEPTED MANUSCRIPT

**Summary** (250 words)

Endometrial polyps are commonly found in association with abnormal uterine bleeding. They affect women of reproductive and post-reproductive age. Their underlying aetiology is debated but most are benign. Hysteroscopy is the gold standard diagnostic test although 2D ultrasound scan, especially with saline or gel contrast, has good accuracy also. Hysteroscopic diagnosis is increasingly performed in an outpatient setting in conscious patients. Furthermore, technological advances have facilitated surgical removal of endometrial polyps in the outpatient setting, which can often be conducted immediately following hysteroscopic diagnosis in the same sitting. This immediacy of treatment and convenience is highly valued by women. Blind polyp removal using large diameter curettes and polyp forceps is outdated and risks incomplete excision, non-retrieval of specimens and uterine trauma. Hysteroscopic removal using mechanical and electrosurgical instruments is successful and has been made increasingly feasible with the recent introduction of bespoke tissue removal systems. The majority of women with heavy menstrual bleeding, intermenstrual bleeding or postmenopausal bleeding report an improvement in symptoms following polypectomy although few placebo controlled trials have been conducted. Further research is needed to better understand the aetiology, natural history, oncogenic potential and significance of these common intrauterine pathologies as well as the benefits of surgical removal including resolution of abnormal bleeding symptoms and detection of serious endometrial disease. The development of a polyp sub-classification may help standardise research so we can more readily address these questions.

**Practice points**

- Endometrial polyps should be considered as a potential cause for abnormal uterine bleeding
- Hysteroscopy is the most accurate outpatient test for diagnosing endometrial polyps. Transvaginal ultrasound especially with saline or gel contrast is an acceptable second best alternative.
- Diagnosis at outpatient hysteroscopy allows for simultaneous surgical removal which is more convenient for most women
- Blind polyp removal using large diameter curettes and polyp forceps is outdated and risks incomplete excision, non-retrieval of specimens and uterine trauma.
- Hysteroscopic removal using mechanical and electrosurgical instruments is safe, feasible and acceptable whether conducted under general anaesthesia or in an outpatient setting with local or no anaesthesia.
- Tissue removal systems appear to be associated with quicker, more successful and less painful outpatient polypectomy and more readily obtain tissue for histological examination as cutting and aspiration of removed polyp tissue occurs simultaneously.
- Polypectomy should be conducted in women with postmenopausal bleeding because 6% harbour atypical endometrial hyperplasia or cancer

**Research Agenda**

- Develop a polyp sub-classification system to standardise research so that the aetiology, natural history, oncogenic potential and clinical significance of endometrial polyps can be better understood
- Conduct further placebo controlled trials to elucidate the effectiveness of endometrial polypectomy on symptoms of abnormal uterine bleeding and better understand their clinical significance and natural history
- Design studies comparing hormonal regulation/suppression of the endometrium on polyp regression, recurrence and associated bleeding symptoms with surgical removal
- Develop operating protocols to optimise the patient experience during outpatient surgical removal of polyps

## References

1. Clark TJ, Middleton LJ, Cooper NAM et al. A randomised controlled trial of outpatient versus inpatient Polyp Treatment (OPT) for abnormal uterine bleeding. *Health Technol Assess* 2015; 19(61)
2. Lopes RGC, Baracat EC, de Albuquerque Neto LC et al. Analysis of estrogen and progesterone-receptor expression in endometrial polyps. *J Minim Invasive Gynaecol* 2007; 14:300-3.
3. Sant'Ana de Almeida EC, Nogueira AA, Candido dos reis FJ et al. Immunohistochemical expression of estrogen and progesterone receptors in endometrial polyps and adjacent endometrium in postmenopausal women. *Maturitas* 2004; 49;3: 229-233.
4. Mittal K, Schwartz L, Goswami S et al. Estrogen and progesterone receptor expression in endometrial polyps. *Int J gynaecol Pathol* 1996; 15:345-8
5. McGurgan P, Taylor LJ, Duffy SR et al. Are endometrial polyps from pre-menopausal women similar to post-menopausal women? An immunohistochemical comparison of endometrial polyps from pre- and post-menopausal women. *Maturitas* 2006; 20;54:277-84.
6. Vanni R, Dal Cin P, Marras S, et al. Endometrial polyp: another benign tumor characterized by 12q13-q15 changes. *Cancer Genet Cytogenet* 1993;68:32-3.
7. Inceboz US, Nese N, Uyar Y et al. Hormone receptor expressions and proliferation markers in postmenopausal endometrial polyps. *Gynecol Obstet Invest* 2006;61:24-8
8. Clark TJ, Gupta JK. *Handbook of Outpatient Hysteroscopy: A Complete Guide to Diagnosis and Therapy*. Boca Raton, FL: CRC Press; 2005
9. Fatemi HM, Kasius JC, Timmermans A et al. Prevalence of unsuspected uterine cavity abnormalities diagnosed by office hysteroscopy prior to in vitro fertilization. *Hum Reprod Oxf Engl* 2010;25:1959-65
10. De Ziegler D. Contrast ultrasound: a simple-to-use phase-shifting medium offers saline infusion sonography-like images. *Fertil Steril* 2009;92:369-73
11. Dreisler E, Stampe Sorensen S et al. Prevalence of endometrial polyps and abnormal uterine bleeding in a Danish population aged 20-74 years. *Ultrasound Obstet Gynecol* 2009;33:102-8
12. Fay TN, Khanem N, Hosking D. Out-patient hysteroscopy in asymptomatic postmenopausal women. *Climacteric J Int Menopause Soc* 1999;2:263-7
13. Reslová T, Tosner J, Resl M et al. Endometrial polyps. A clinical study of 245 cases. *Arch Gynecol Obstet* 1999;262:133-9
14. Cohen I. Endometrial pathologies associated with postmenopausal tamoxifen treatment. *Gynecol Oncol* 2004;94:256-66
15. Chalas E, Costantino JP, Wickerham D et al. Benign gynecologic conditions among participants in the Breast Cancer Prevention Trial. *Am J Obstet Gynecol* 2005;192:1230-7; discussion 1237-9
16. Bakour SH, Khan KS, Gupta JK. The risk of premalignant and malignant pathology in endometrial polyps. *Acta Obstet Gynecol Scand* 2002;8:182-3
17. Perrone G, DeAngelis C, Critelli C et al. Hysteroscopic findings in postmenopausal abnormal uterine bleeding: a comparison between HRT users and non-users. *Maturitas* 2002;43:251-5
18. Clevenger-Hoeft M, Syrop CH, Stovall DW et al. Sonohysterography in premenopausal women with and without abnormal bleeding. *Obstet Gynecol* 1999;94:516-20

19. Elfayomy AK, Habib FA, Alkabalawy MA. Role of hysteroscopy in the detection of endometrial pathologies in women presenting with postmenopausal bleeding and thickened endometrium. *Arch Gynecol Obstet* 2012;285:839–43
20. Munro MG, Critchley HOD, Fraser IS. The FIGO systems for nomenclature and classification of causes of abnormal uterine bleeding in the reproductive years: who needs them? *Am J Obstet Gynecol* 2012;207:259–65
21. Lieng M, Istre O, Sandvik L et al. Prevalence, 1-year regression rate, and clinical significance of asymptomatic endometrial polyps: cross-sectional study. *J Minim Invasive Gynecol* 2009;16:465–71
22. DeWaay DJ, Syrop CH, Nygaard IE et al. Natural history of uterine polyps and leiomyomata. *Obstet Gynecol* 2002;100:3-7.
23. Lieng M, Istre O, Qvigstad E. Treatment of endometrial polyps: a systematic review. *Acta Obstet Gynecol Scand* 2010;89:992–1002.
24. Antunes A Jr, Costa-Paiva L, Arthuso M et al. Endometrial polyps in pre- and postmenopausal women: factors associated with malignancy. *Maturitas* 2007;57:415–21
25. Gregoriou O, Konidaris S, Vrachnis N et al. Clinical parameters linked with malignancy in endometrial polyps. *Climacteric J Int Menopause Soc* 2009;12:454–8
26. Wang J-H, Zhao J, Lin J. Opportunities and risk factors for premalignant and malignant transformation of endometrial polyps: management strategies. *J Minim Invasive Gynecol* 2010;17:53–8
27. Ferrazzi E, Zupi E, Leone FP et al. How often are endometrial polyps malignant in asymptomatic postmenopausal women? A multicenter study. *Am J Obstet Gynecol* 2009;200:235.e1–6
28. Orvieto R, Bar-Hava I, Dicker D et al. Endometrial polyps during menopause: characterization and significance. *Acta Obstet Gynecol Scand* 1999;78:883–6.
29. Savelli L, De Iaco P, Santini D et al. Histopathologic features and risk factors for benignity, hyperplasia, and cancer in endometrial polyps. *Am J Obstet Gynecol* 2003;188:927–31
30. Ben-Arie A, Goldchmit C, Laviv Y et al. The malignant potential of endometrial polyps. *Eur J Obstet Gynecol Reprod Biol* 2004;115:206–10
31. Anastasiadis PG, Koutlaki NG, Skaphida PG et al. Endometrial polyps: prevalence, detection, and malignant potential in women with abnormal uterine bleeding. *Eur J Gynaecol Oncol* 2000;21:180–3
32. Shushan A, Revel A, Rojansky N. How often are endometrial polyps malignant? *Gynecol Obstet Invest* 2004;58:212–15
33. Kedar RP, Bourne TH, Powles TJ et al. Effects of tamoxifen on uterus and ovaries of postmenopausal women in a randomised breast cancer prevention trial. *Lancet* 1994;343:1318–21
34. Nathani F, Clark TJ. Uterine polypectomy in the management of abnormal uterine bleeding: a systematic review. *J Minim Invasive Gynecol* 2006;13:260–8
35. Martinez-Perez O, Perez-Medina T, Bajo-Arenas J. Ultrasonography of endometrial polyps. *Ultrasound Rev Obstet Gynaecol* 2003; 3:43
36. American Association of Gynaecologic Laparoscopists. AAGL Practice report: Practice Guidelines for the Diagnosis and Management of Endometrial Polyps; *J Minim Invasive Gynaecol* 2012 Jan-Feb; 19 (1); 1:3-10

37. Oldani S, Moschetta M, De Giorgi O et al. The role of transvaginal ultrasonography and outpatient diagnostic hysteroscopy in the evaluation of patients with menorrhagia. *Hum Reprod* 1997; 12:1768-1771
38. Jakab A, Ovari L, Juhasz B et al. Detection of feeding artery improves the ultrasound diagnosis of endometrial polyps in asymptomatic patients. *Eur J Obstet Gynaecol Reprod Biol* 2005; 119:103-107
39. Schwarzler P, Concin H, Bosch H et al. An evaluation of sonohysterography and diagnostic hysteroscopy for the assessment of intrauterine pathology. *Ultrasound Obstet Gynaecol* 1998; 11: 337-342
40. De Kroon CD, de Bock GH, Dieben SW et al. Saline contrast hysterosonography in abnormal uterine bleeding: a systematic review and meta-analysis. *BJOG* 2003;110:938-47
41. La Torre R, De Falice C, De Angelis C et al. Transvaginal sonographic evaluation of endometrial polyps; a comparison with two dimensional and three dimensional contrast sonography. *Clin Exp Obstet Gynaecol* 1999; 26:171-173
42. Royal College of Obstetricians and Gynaecologists. Consent Advice No 1. Diagnostic hysteroscopy under general anaesthesia. 2008
43. Van Dongen H, de Kroon CD, Jacobi CE et al. Diagnostic hysteroscopy in abnormal uterine bleeding: a systematic review and meta-analysis. *BJOG* 2007;114:664-75
44. Lo KW, Yuen PM. The role of outpatient diagnostic hysteroscopy in identifying anatomic pathology and histopathology in the endometrial cavity. *J Am Assoc Gynaecol laparosc* 2000; 7:381-385.
45. Clark TJ, Voit D, Gupta JK et al. Accuracy of hysteroscopy in the diagnosis of endometrial cancer and hyperplasia: a systematic quantitative review. *JAMA* 2002;288:1610–21
46. Nagele F, O'Connor H, Davies A et al. 2500 Outpatient diagnostic hysteroscopies. *Obstet Gynaecol* 1996; 88:87-92
47. Zlatkov V, Kostova P, Barzakov G et al. Flexible hysteroscopy in irregular uterine bleeding. *J BUON* 2007; 12:53-56.
48. Gimplerson RJ, Rappold HO. A comparison study between panoramic hysteroscopy with directed biopsies and dilatation and curettage. A review of 276 cases. *J Obstet Gynaecol* 1988; 158:489-492
49. Pasqualotto EB, Margossian H, Price LL et al. Accuracy of preoperative diagnostic tools and outcome of hysteroscopic management of menstrual dysfunction. *J Am Assoc Gynaecol Laparosc* 2000; 7:201-209
50. Clark TJ, Khan KS, Gupta JK. Current practice for the treatment of benign intrauterine polyps: a national questionnaire survey of consultant gynaecologists in UK. *Eur J Obstet Gynecol Reprod Biol* 2002;103:65–7
51. Timmermans A, van Dongen H, Mol BW et al. Hysteroscopy and removal of endometrial polyps: a Dutch survey. *Eur J Obstet Gynecol Reprod Biol* 2008;138:76–9.
52. Van Dijk LJEW, Breijer MC, Veersema S et al. Current practice in the removal of benign endometrial polyps: a Dutch survey. *Gynecol Surg* 2012;9:163–8
53. Lee SC, Kaunitz AM, Sanchez-Ramos L et al. The oncogenic potential of endometrial polyps: a systematic review and meta-analysis. *Obstet Gynecol* 2010;116:1197–205
54. Lieng M, Istre O, Sandvik L et al. Clinical effectiveness of transcervical polyp resection in women with endometrial polyps: randomized controlled trial. *J Minim Invasive Gynecol* 2010;17:351–7

55. Timmermans A, Veersema S, van Kerkvoorde TC et al. Should endometrial polyps be removed in patients with postmenopausal bleeding? An assessment of study designs and report of a failed randomised controlled trial. *BJOG* 2009;116:1391–5
56. Van Hanegem N, Breijer MC, Sloekers SA et al. Diagnostic workup for postmenopausal bleeding: a randomised controlled trial. *BJOG*. 2016 May 26
57. Vercellini P, Trespidi L, Bramante T et al. Gonadotropin releasing hormone agonist treatment before hysteroscopic endometrial resection. *Int J Gynaecol Obstet* 1994;45:235–9
58. Oguz S, Sargin A, Kelekci S et al. The role of hormone replacement therapy in endometrial polyp formation. *Maturitas* 2005;50:231–6.
59. Gardner FJE, Konje JC, Bell SC et al. Prevention of tamoxifen induced endometrial polyps using a levonorgestrel releasing intrauterine system long-term follow-up of a randomised control trial. *Gynecol Oncol* 2009;114:452–6
60. Grimes DA. Diagnostic dilation and curettage: a reappraisal. *Am J Obstet Gynecol* 1982;142:1–6
61. MacKenzie IZ, Bibby JG. Critical assessment of dilatation and curettage in 1029 women. *Lancet* 1978;2:566–8
62. Bettocchi S, Ceci O, Vicino M et al. Diagnostic inadequacy of dilatation and curettage. *Fertil Steril* 2001;75:803–5
63. Svirsky R, Smorgick N, Rozowski U et al. Can we rely on blind endometrial biopsy for detection of focal intrauterine pathology? *Am J Obstet Gynecol* 2008;199:115.e1–3
64. Bettocchi S, Ceci O, Nappi L et al. Operative office hysteroscopy without anesthesia: analysis of 4863 cases performed with mechanical instruments. *J Am Assoc Gynecol Laparosc* 2004;11:59–61
65. Timmermans A, Veersema S. Ambulatory transcervical resection of polyps with the Duckbill polyp snare: a modality for treatment of endometrial polyps. *J Minim Invasive Gynecol* 2005;12:37–9
66. Van Dongen, H., Emanuel, M.H., Wolterbeek, R et al. Hysteroscopic morcellator for removal of intrauterine polyps and myomas: a randomized controlled pilot study among residents in training. *J. Minim. Invasive Gynecol* 2008; 15, 466–471
67. Smith PP, Middleton LJ, Connor M et al. Hysteroscopic morcellation compared with electrical resection of endometrial polyps: a randomized controlled trial. *Obstet Gynecol*. 2014 Apr;123(4):745–51
68. Cooper NA, Smith P, Khan KS et al. Vaginoscopic approach to outpatient hysteroscopy: a systematic review of the effect on pain. *BJOG*. 2010;117:532–9
69. Garuti G, Centinaio G, Luerti M. Outpatient hysteroscopic polypectomy in postmenopausal women: a comparison between mechanical and electro-surgical resection. *J Minim Invasive Gynecol* 2008;15:595–600
70. Betjes HE, Hanstede MMF, Emanuel M-H et al. Hysteroscopic myomectomy and case volume hysteroscopic myomectomy performed by high- and low-volume surgeons. *J Reprod Med* 2009;54:425–8; 94
71. Batra N, Khunda A, O'Donovan PJ. Hysteroscopic myomectomy. *Obstet Gynecol Clin North Am* 2004;31:669–85
72. Overton C, Hargreaves J, Maresh M. A national survey of the complications of endometrial destruction for menstrual disorders: the MISTLETOE study. *Minimally Invasive Surgical Techniques—Laser, EndoThermal or Endorescetion*. *BJOG* 1997;104:1351–9



73. Papalampros P, Gambadauro P, Papadopoulos N et al. The mini-resectoscope: a new instrument for office hysteroscopic surgery. *Acta Obstet Gynecol Scand*. 2009;88(2):227-30
74. Kung RC, Vilos GA, Thomas B et al. A new bipolar system for performing operative hysteroscopy in normal saline. *J Am Assoc Gynecol Laparosc* 1999;6:331-6
75. Clark TJ, Godwin J, Khan KS et al. Ambulatory endoscopic treatment of symptomatic benign endometrial polyps: feasibility study. *Gynaecol Endosc* 2002;11:91-7.
76. Vilos GA. Intrauterine surgery using a new coaxial bipolar electrode in normal saline solution (Versapoint): a pilot study. *Fertil Steril* 1999;72:740-3
77. Emanuel MH, Wamsteker K. The Intra Uterine Morcellator: a new hysteroscopic operating technique to remove intrauterine polyps and myomas. *J Minim Invasive Gynecol* 2005;12:
78. Cooper NA, Clark TJ, Middleton L et al. Outpatient versus inpatient uterine polyp treatment for abnormal uterine bleeding: randomised controlled non-inferiority study. *BMJ* 2015. 23;350:h1398.
79. Cooper NA, Barton PM, Breijer M et al. Cost-effectiveness of diagnostic strategies for the management of abnormal uterine bleeding (heavy menstrual bleeding and post-menopausal bleeding): a decision analysis. *Health Technol Assess* 2014;18
80. Cooper NA, Khan KS, Clark TJ. Local anaesthesia for pain control during outpatient hysteroscopy: systematic review and meta-analysis. *BMJ*. 2010;340:c1130
81. Clark TJ, Cooper N A M, Kremer C. Green-top guideline No.59- Best Practice in Outpatient Hysteroscopy. [First]. 2011. Royal College of Obstetricians and Gynaecologists
82. Diwakar L, Roberts TE, Cooper N M et al. OPT trial collaborative group. An economic evaluation of outpatient versus inpatient polyp treatment for abnormal uterine bleeding. *BJOG*. 2016;123:625-31
83. Lima G, Girão M. Pólipos uterinos. In: Lima GR, Girão MJB, Baracat EC, editors. *Ginecologia de Consultório*. São Paulo: EPM; 2003. pp. 243-6.
84. Taylor LJ, Jackson TL, Reid JG et al. The differential expression of oestrogen receptors, progesterone receptors, Bcl-2 and Ki67 in endometrial polyps. *BJOG* 2003;110:794-8
85. Hulka CA, Hall DA, McCarthy K, Simeone JF. Endometrial polyps, hyperplasia, and carcinoma in postmenopausal women: differentiation with endovaginal sonography. *Radiology*. 1994;191:755-758
86. Schorge J, Schaffer JI, Halvorson LM, et al. Chapter 8. Abnormal uterine bleeding. In: Schorge JO, Halvorson LM, Hoffman BL, Bradshaw KD, Cunningham FG, editors. *Williams Gynecology*. Columbus: McGraw-Hill Professional. 2008
87. Grasel RP, Outwater EK, Siegelman ES et-al. Endometrial polyps: MR imaging features and distinction from endometrial carcinoma. *Radiology*. 2000;214:47-52

#### **Conflict of interest statement**

Prof TJ Clark reports receiving honoraria for training from the Hologic, Smith & Nephew and Ethicon who make endoscopic instruments suitable for removing uterine pathologies such as polyps (Myosure, Truclear and Versapoint respectively). He received £40,000 funding from Smith & Nephew to evaluate the product TruClear for removing uterine polyps in a clinical research trial.

**Table 1**

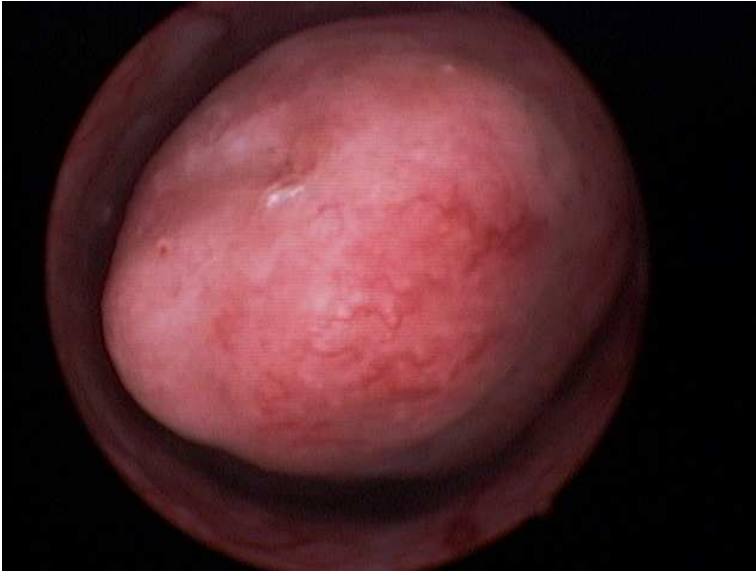Definition of an endometrial polyp according to diagnostic test

Diagnostic test	Definition
Hysteroscopy	A discrete outgrowth of endometrium, attached by a pedicle, which moves with the flow of the distension medium. Polyps may be pedunculated or sessile, single or multiple and vary in size (the variable amount of glands, stroma and blood vessels that constitute the polyp will influence their macroscopic appearance[8.]
Ultrasound	Non- specific endometrial thickening or a focal mass identified as an echogenic lesion which disturbs the midline endometrial echo but does not disrupt the interface between the myometrium and endometrium. The lesion is usually oval shaped with a homogenous texture although hypoechoic cystic spaces may be seen. Blood flow may be identified within a feeding vessel extending to the polyp on colour Doppler imaging. Saline infusion sonography and 3D ultrasound help delineate the borders of the intra-cavity lesion. [35, 85,86]
Hysterosalpingogram	Filling defects within the uterine cavity
Magnetic resonance imaging	Isointense (Tesla 1) or hypointense (Tesla2) masses within the uterine cavity. Tesla 1 contrast enhancement with gadolinium can show either homogeneous or heterogeneous enhancement. [87]
Histological sampling <sup>1</sup>	Endometrial tissue showing at least two of: (i) glandular architectural disarray, (ii) stromal fibrosis and (iii) enlarged, thick-walled stromal blood vessels. <i>Benign 'simple' polyps</i> may be covered with functional endometrium (reproductive age) or atrophic (post-reproductive age). They may be described as glandular-cystic, fibrous, glandular-fibrous according to the relative preponderance of glandular and stromal components. Adenomyomatous polyps contain prominent bundles of smooth muscle within the stroma and adenomatous polyps have many glands with an intensively proliferating epithelium. <i>Hyperplastic polyps</i> have a hyperplastic epithelium with or without cytological atypia. Polyps may more rarely contain <i>intraepithelial carcinomas</i> or be frankly <i>malignant</i> .

<sup>1</sup> Biopsy may be blind or directed; the oval, polyp shape will be seen if surgically removed en bloc

**Figure 1**

Hysteroscopic appearance of an endometrial polyp



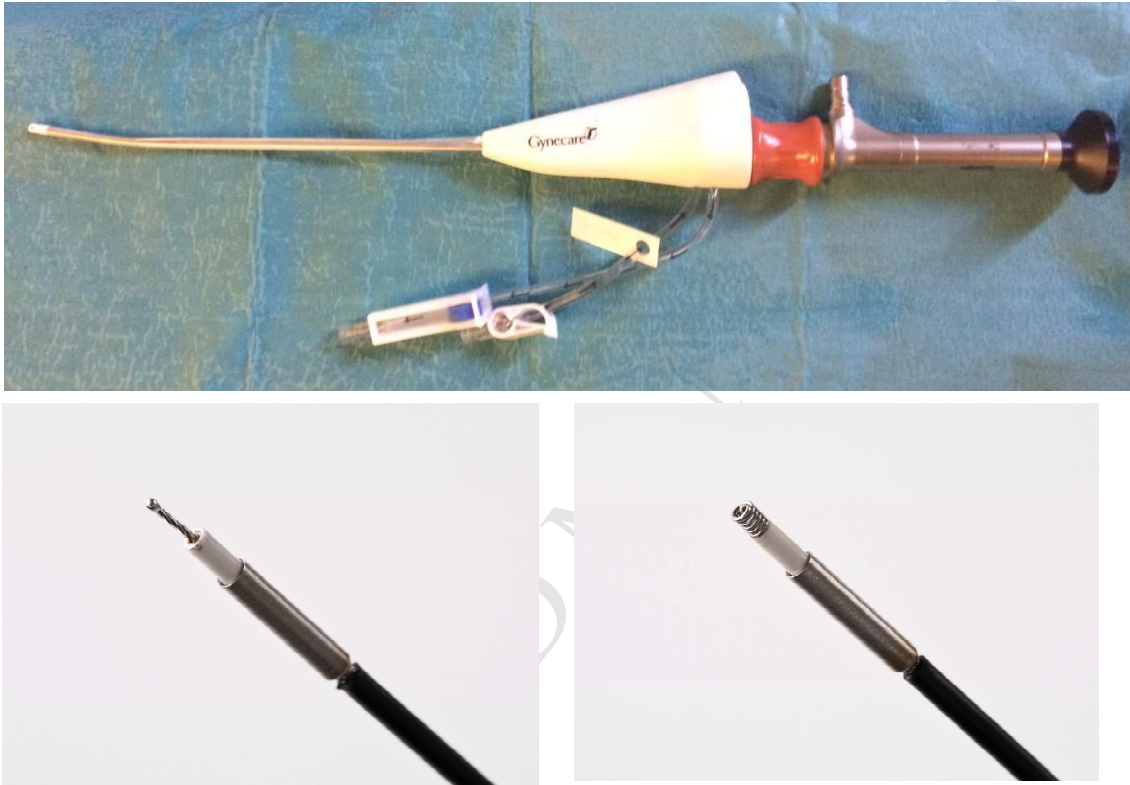
**Figure 2**

Small diameter, 30° rigid continuous flow operating hysteroscope. 5 Fr mechanical instruments shown for use down the working channel



**Figure 3**

Small diameter, 0° Alphascope®. Note the disposable outer sheath containing the inflow and working channels. The sheath can be rotated to manipulate the hysteroscopic instruments within the uterine cavity. Mechanical (5 & 7 Fr) and electro-surgical bipolar electrodes (5 Fr) can be used. The Versapoint® twizzle tip and spring tip electrodes are shown. These 5 Fr electrodes can be used with other types of rigid operating hysteroscope



**Figure 4**

Truclear® Tissue Removal System. The system consists of a 0°bespoke hysteroscope generator to power the rotating blades within the disposable handpiece which in turn is attached to external suction tubing. Tissue is simultaneously cut and aspirated providing clear views and immediate tissue removal. Note the off-set proximal eye piece to allow the instrument to be passed down the working channel.

