

Fibroids

Lumsden, Mary Ann; Hamoodi, Ibraheem; Gupta, Janesh; Hickey, Martha

DOI:

[10.1136/bmj.h4887](https://doi.org/10.1136/bmj.h4887)

License:

Creative Commons: Attribution-NonCommercial (CC BY-NC)

Document Version

Publisher's PDF, also known as Version of record

Citation for published version (Harvard):

Lumsden, MA, Hamoodi, I, Gupta, J & Hickey, M 2015, 'Fibroids: diagnosis and management', *BMJ*, vol. 351, pp. h4887. <https://doi.org/10.1136/bmj.h4887>

[Link to publication on Research at Birmingham portal](#)

Publisher Rights Statement:

Checked for eligibility: 22/01/2016. The BMJ's default licence for open access publication of research is the Creative Commons Attribution Non Commercial licence (CC BY-NC 4.0).

General rights

Unless a licence is specified above, all rights (including copyright and moral rights) in this document are retained by the authors and/or the copyright holders. The express permission of the copyright holder must be obtained for any use of this material other than for purposes permitted by law.

- Users may freely distribute the URL that is used to identify this publication.
- Users may download and/or print one copy of the publication from the University of Birmingham research portal for the purpose of private study or non-commercial research.
- User may use extracts from the document in line with the concept of 'fair dealing' under the Copyright, Designs and Patents Act 1988 (?)
- Users may not further distribute the material nor use it for the purposes of commercial gain.

Where a licence is displayed above, please note the terms and conditions of the licence govern your use of this document.

When citing, please reference the published version.

Take down policy

While the University of Birmingham exercises care and attention in making items available there are rare occasions when an item has been uploaded in error or has been deemed to be commercially or otherwise sensitive.

If you believe that this is the case for this document, please contact UBIRA@lists.bham.ac.uk providing details and we will remove access to the work immediately and investigate.



CLINICAL REVIEW

Fibroids: diagnosis and management

Mary Ann Lumsden *professor of gynaecology and medical education*¹, Ibraheem Hamoodi *specialist trainee and research fellow*¹, Janesh Gupta *professor of obstetrics and gynaecology*², Martha Hickey *professor of obstetrics and gynaecology*³

¹University of Glasgow, Glasgow Royal Infirmary Campus, Glasgow G31 2ER, UK; ²University of Birmingham, Birmingham Women's Hospital, Birmingham, UK; ³The University of Melbourne and the Royal Women's Hospital, Royal Women's Hospital, Parkville, Melbourne, Australia

Uterine leiomyomas (fibroids) are the most common benign tumours in women. They may be single or multiple and their size varies from a few millimetres to 30 cm or more. By age 50 nearly 70% of white women and more than 80% of black women have had at least one fibroid.¹ Box 1 lists the several risk factors for fibroids. Symptomatic fibroids are often managed surgically, and this confers a considerable burden on healthcare costs.² This review aims to update non-specialists on the investigation and management of fibroids. Gaps in current knowledge are highlighted.

What are fibroids and where are they found?

Fibroids are a mixture of smooth muscle cells and fibroblasts, which form hard, round, whorled tumours in the myometrium. The pathophysiology of fibroids remains unknown, although it is hypothesised that each fibroid is derived from a mutation in a single smooth muscle cell.³

The uterus is the commonest site for fibroids (fig 1⇓). The location may have an effect on symptoms and quality of life. For example, submucous fibroids may lead to heavy menstrual bleeding and fertility problems and large fibroids may occupy two or more locations and can extend from the endometrial cavity to the serosal surface.

What controls the growth of fibroids?

Oestrogen and progesterone control the proliferation and maintenance of uterine fibroids, and most medical treatments act by inhibiting the production of sex steroids or their action. The primary action of oestrogen is thought to be mediated through induction of progesterone receptor expression, thereby allowing leiomyomas to respond to progesterone.⁹ Hormonal replacement therapy may cause some growth of fibroids, but this is of uncertain clinical importance.¹⁰

What is the clinical course of uterine fibroids?

Fibroids are rare in girls before menarche and regress after the menopause. One retrospective study of 122 premenopausal women who had at least two transvaginal ultrasound scans over a median interval of two years reported that fibroids tended to grow by around 35% of their volume each year, and that small fibroids (<2 cm) or intramural fibroids grew most quickly,¹¹ although this was variable.

How do women with fibroids present?

Fibroids tend to be asymptomatic. When symptoms do occur, however, menstrual problems, particularly heavy menstrual bleeding and pressure symptoms, are typical (box 2)¹² and can have a negative effect on quality of life. They usually require treatment.¹³ The size of fibroids does not necessarily determine symptoms.

When do fibroids need to be investigated?

Fibroids are common, and with the widespread availability of high resolution ultrasonography, they are often diagnosed incidentally.

Women presenting in primary care with symptoms suggestive of fibroids should have their gynaecological history evaluated, including cervical screening, and should undergo a pelvic examination for any masses, a haemoglobin estimation to check for iron deficiency anaemia, and, if urinary symptoms are present, midstream urine testing to exclude a urinary tract infection. Diagnostic uncertainty, association with problematic symptoms, or any clinical or radiological suspicion of malignancy should prompt referral for further investigations. Women with asymptomatic fibroids, if the diagnosis is certain, often do not need further investigation or treatment.

Correspondence to: M A Lumsden Maryann.Lumsden@glasgow.ac.uk

Extra material supplied by the author (see <http://www.bmj.com/content/351/bmj.h4887?tab=related#datasupp>)

References w1-w34 are available on bmj.com

The bottom line

- Fibroids are commonly asymptomatic and usually do not require treatment once the diagnosis is confirmed by ultrasonography or, when required, by magnetic resonance imaging
- Women should be made aware of all available treatment options; medical, radiological, and surgical, and why they may or may not be appropriate
- Medical treatments for heavy menstrual bleeding may be effective in those with fibroids, but there is relatively little evidence to support this
- Women should also understand that advice on treatment is often based on inadequate evidence, particularly for well established treatments such as myomectomy
- Hysterectomy is effective, but other conservative surgical and radiological treatments may be preferable and treatment should be individualised
- Submucosal and possibly intramural fibroids may decrease pregnancy rates; however, evidence to support a role for myomectomy in enhancing fertility by any route is inconclusive

Sources and selection criteria

The literature search used a combination of MeSH, text words, and appropriate word variants of "fibroids" and "leiomyoma". We searched Medline and Embase, Cochrane Reviews, personal references and reference lists in general articles on uterine fibroids. Searching was limited to publications in English and to studies in women and we have included reference to evidence based guidelines, such as those by the National Institute of Health and Care Excellence.

Box 1 Risk factors for uterine fibroids

- Race—incidence is higher in black and Asian women than in white women, and multiple fibroids are more common¹
- Heredity—risk is higher in women with first degree relatives who have fibroids³
- Age—incidence increases with age during reproductive years⁴
- Earlier menarche (before age 11)⁴
- Pregnancy—full term pregnancy is related to lower rates of fibroids⁵; fibroids are more common in nulliparous women⁶
- Hormonal contraception—progestin only injectable contraceptives and oral contraceptives reduce the risk of fibroids^{6,7}
- Obesity—weight gain and central distribution of body fat increase the risk of fibroids⁸

Box 2 Symptoms associated with uterine fibroids

- Heavy menstrual bleeding
- Pelvic pain
- Secondary dysmenorrhoea
- Abdominal distension or distortion
- "Pressure" symptoms—for example, pelvic pressure or discomfort
- Urinary tract problems such as frequency, urgency, urinary incontinence, and hydronephrosis
- Non-specific bowel problems
- Subfertility

The incidence of symptoms depends on the population studied, although a recent systematic review suggests that menstrual disorder and pelvic pain are the most common symptoms¹⁴

When should women be referred to secondary care?

Women with fibroids that cause symptoms who have not responded to initial treatments require referral to secondary care, and some may be suitable for newer uterine conserving treatments should this be their preference. As fibroids do not generally cause irregular bleeding, such bleeding should prompt earlier referral, as should the other symptoms or signs listed in box 3. Women with subfertility and uterine fibroids should undergo standard, preliminary investigations as recommended by the local fertility clinic.

What imaging investigations are useful in the assessment of fibroids?

If fibroids are suspected, ultrasound scanning is the initial method of screening that should be performed after an abdominal and pelvic examination. In most instances it can

determine the size, location, and number of uterine fibroids and may indicate associations between fibroids and symptoms.¹⁵ For example, a fibroid pushing on the bladder may help explain urinary symptoms. Since the diagnosis of leiomyosarcoma is based on histology, imaging, including ultrasonography, cannot be used to diagnose this condition. A systematic review has shown that delineation of submucous fibroids can be improved by intracavity saline infusion, with comparable accuracy to hysteroscopy. If hysteroscopy is required this should be performed in a dedicated outpatient setting (fig 2⇓). In most women hysteroscopy usually requires no anaesthesia. However, transvaginal ultrasonography and diagnostic hysteroscopy should be considered as complementary investigations and not alternatives in planning for operative hysteroscopy.^{16 17}

Magnetic resonance imaging is required in some cases to provide enhanced visualisation of fibroids (box 4 and fig 3⇓). However, similar to ultrasonography, it cannot diagnose malignancy with certainty, and current studies are exploring the possibility that such potential may be increased by new types of imaging.^{18 19}

Box 3 Red flag symptoms that might suggest other diseases and require referral

- Intermenstrual or postcoital bleeding
- Sudden onset of pain
- Increase in fibroid size in postmenopausal women

Computed tomography is rarely helpful in the management of uterine fibroids.

When do fibroids need to be treated and how do doctors and patients select the best treatment?

Fibroids only require treatment when they cause symptoms.²² Hysterectomy, myomectomy, or uterine artery embolisation should be considered for fibroids (>3 cm) that cause heavy menstrual bleeding and affect quality of life.²³ The most important clinical factor in determining any potential treatment option will be whether fertility or preservation of the uterus, or both, is desired. This usually steers the options between observational, medical, radiological, uterine preserving surgery, and hysterectomy.

Hysterectomy is the definitive method of resolving symptoms associated with uterine fibroids but is permanently contraceptive and is considered by many women to be more invasive than other methods.

What treatments can be considered in general practice without referral to specialist care?

Standard medical treatments for heavy menstrual bleeding may also be effective when such bleeding is associated with fibroids and may reduce the impact of heavy menstrual bleeding. There is less evidence supporting these medical treatments in the presence of uterine fibroids compared with heavy menstrual bleeding with normal uterine morphology. Table 1⇓ provides further details.

Which are the most effective medical treatments?

Medical treatments for fibroids should be targeted against symptoms. Mefenamic acid and tranexamic acid, which may reduce heavy menstrual bleeding and pain, are safe and generally well tolerated. Since they only need to be taken during menses, major side effects are uncommon.

Hormonal treatments for heavy menstrual bleeding in particular include the oral contraceptive pill, oral norethisterone, and the levonorgestrel releasing intrauterine system, although studies of their efficacy have excluded women with anything other than small uterine fibroids. Both progesterone and oestrogen can, however, promote the growth of fibroids.^{24 25} Selective progesterone receptor modulators now offer an alternative in the medical management of fibroids. Several randomised controlled trials have shown that these agents reduce blood loss and shrink fibroids.^{26 27} Ulipristal acetate has recently been approved for short term use in preparation for surgery (three months) and long term intermittent use (≥12 months) where surgery can be avoided.

Gonadotrophin releasing hormone agonists are well established treatments that can be used in primary care, although usually initiated in secondary care, to relieve fibroid associated

symptoms, including those related to size. These agonists are only effective while treatment is ongoing, and symptoms generally recur on stopping treatment.

What treatments are undertaken in secondary care?

Radiological treatments

Uterine artery embolisation

Uterine artery embolisation aims to block the blood supply to the uterus (fig 4⇓). This leads to ischaemic degeneration of fibroids, although the myometrium obtains a new blood supply from collateral circulations (ovarian and vaginal). It is an effective and safe treatment for fibroids.²⁸ A recent meta-analysis of randomised controlled trials measuring patient satisfaction rates of uterine artery embolisation versus surgery (hysterectomy or myomectomy) showed that embolisation was equivalent to surgery at 1-5 years.²⁹ Major complications with uterine artery embolisation are rare, but minor complications such as nausea, pain, and vaginal discharge are more common than with surgery, and reinterventions are more often needed in the embolisation group within five years. Table 2⇓ summarises this evidence, considered in the updated Cochrane review of five randomised controlled trials.²⁹

The impact of uterine artery embolisation on fertility and pregnancy outcome is not known³⁰ and is the subject of an ongoing UK multicentre randomised controlled trial.

Surgical treatments

Surgery for uterine fibroids either removes fibroid tissue only (myomectomy) or removes the uterus and fibroids (hysterectomy). Both procedures can be performed by hysteroscopy or laparoscopy, or through abdominal incisions, although the latter is often preferred for large fibroids. The main indication for myomectomy rather than hysterectomy is the preservation of fertility or a desire to avoid hysterectomy. Table 1 summarises the advantages and disadvantages of these treatments.

Myomectomy

Myomectomy removes fibroids but preserves the uterus. Although intraoperative bleeding requiring transfusion may occur in up to 30% of women,³¹ the chance of emergency hysterectomy is rare, although the possibility should be part of the consent process. A recent systematic review discusses methods to minimise blood loss.³² Systematic reviews of surgical treatment for uterine fibroids concluded that evidence showing that myomectomy (either open, laparoscopic, or hysteroscopic) improves fertility or pregnancy outcomes is inconclusive.³³ Even studies of hysteroscopic myomectomy for submucous fibroids where observational studies have been undertaken to study changes in fertility, were not of a high quality enough for a Cochrane review to reach a conclusion.^{34 35 36} The evidence base does not support myomectomy, where subfertility is the only problem.

No robust data comparing fertility sparing options such as uterine artery embolisation with myomectomy for these

Box 4 Information available from magnetic resonance imaging and ultrasonography*Pelvic ultrasonography**

Possibly both transabdominal and transvaginal to identify:

- the size and location of fibroids and whether single or multiple
- when fibroids are large, to exclude hydronephrosis
- whether a submucous fibroid is distorting the uterine cavity (improved with addition of saline infusion sonography)^{16 17}
- change in size of single fibroids

*Magnetic resonance imaging**

Magnetic resonance imaging is more costly and less easily available than ultrasonography but may be required:

- when the results of ultrasonography are inconclusive
- when more information is needed about the size and location of fibroids since ultrasonography is less able to delineate very large or multiple fibroids
- before uterine artery embolisation or magnetic resonance guided focused ultrasound, to determine the size and location of fibroids²⁰
- to assess vascularity, which may contribute to predicting the efficacy of uterine artery embolisation, particularly if contrast agents are used²¹

*Neither investigation can be used to diagnose malignancy

outcomes exist. Level 1 data show that quality of life outcomes are equivalent between the two interventions.³⁷

Few studies have prospectively measured the risks associated with myomectomy and its effect on subsequent pregnancy. Estimates of major complications are around 2%.³⁸ Regardless of the route, myomectomy may increase the need for operative delivery and the risk of uterine rupture.³⁹ However, a multicentre study did not show an increased risk of adverse outcomes for the fetus after myomectomy.⁴⁰

Large fibroids are usually removed by open myomectomy. In some women, however, submucous fibroids (usually <5 cm in diameter) can be resected hysteroscopically; few studies have investigated the effect of this on heavy menstrual bleeding, although some observational studies have noted improvement.^{41 42} Thus evidence that hysteroscopic removal of submucous fibroids improves either the chance of pregnancy in women with otherwise unexplained subfertility or symptoms is insufficient to draw conclusions.³⁶

Hysterectomy

Hysterectomy effectively and permanently resolves symptoms associated with uterine fibroids. Hysterectomy has a mortality rate of 0.6 to 1.6 per 1000 women. No studies have compared the incidence of complications between hysterectomy and myomectomy, although a large observational study found an increase in complications of hysterectomy with large fibroids.⁴³

What is the relation between fibroids and fertility?

The exact relation between fibroids and infertility is not well understood. Some evidence suggests that submucosal fibroids cause subfertility, although the impact of intramural fibroids is uncertain. Subserosal fibroids do not seem to be important in this context. Observational studies support myomectomy for submucosal fibroids, although a recent Cochrane review was inconclusive.^{36 44 45} The effect of intramural fibroids is uncertain and current consensus does not support their removal to improve fertility.^{44 46}

What happens to fibroids during pregnancy?

Data from the United States indicate that around 18% of African-American women and around 8% of European-American women have uterine fibroids when scanned

in early pregnancy, although it was not clear when they developed.⁴⁷ A systematic review of 23 studies concluded that while most fibroids are asymptomatic, spontaneous miscarriage rates were statistically significantly higher in women with fibroids, although no difference was observed in preterm delivery rates.⁴⁸ However, older reproductive age increases the risk of both fibroids and miscarriage, thus distorting the picture. Fibroids adjacent to the placenta are more likely to be associated with bleeding in early pregnancy and spontaneous miscarriage.⁴⁸ Acute pain in pregnancy (for example, caused by “red degeneration” (increase in fibroid size outstrips the blood supply, with resulting ischaemia) or bleeding secondary to fibroids) is uncommon but should prompt referral for specialist advice. Treatment of fibroids is only required during pregnancy if acute complications occur.⁴⁸

Is there a risk of malignant transformation?

Leiomyosarcomas are rare malignancies that may be difficult to distinguish clinically from fibroids. They can only be diagnosed reliably by histopathology. This is a potential cause of concern when fibroids are left untreated or managed conservatively. A recent meta-analysis concluded that leiomyosarcomas are diagnosed unexpectedly after surgery for supposed benign fibroids in about 2.94 per 1000 women (95% confidence interval 1.8 to 4.1), or 1 in 340 women. Risks increase with age, from fewer than one case per 500 for women aged less than 30 to 1 in 98 for women aged 75-79.⁴⁹ The true prevalence of uterine sarcomas in presumed fibroids is not known, given the wide range of prevalence.

Fibroids that grow rapidly, particularly after menopause or despite the use of gonadotrophin releasing hormone agonists (when fibroids would be expected to decrease in size), often cause concern and should prompt specialist referral. However, this clinical picture is not sensitive or specific in discriminating leiomyosarcomas from benign fibroids, but referral and further evaluation will determine what further investigations or treatment, if any, are required.

We thank Ginette Camps-Walsh (FEmISA) for her helpful input.

Contributors: MAL was the lead on compiling and writing the article as well as helping with the literature search. She is the guarantor. IH undertook the initial literature review and helped with drafting the article. MH and JG supported the searching of the literature and ensured no important references were missed as well as contributing to the writing up.

Additional educational resources

Resources for healthcare professionals

- Lumsden MA. Embolization versus myomectomy versus hysterectomy: which is best, when? *Hum Reprod* 2000;17:253-9—a review article
- Uterine artery embolisation in the management of uterine fibroids (www.rcog.org.uk/en/guidelines-research-services/guidelines/uterine-artery-embolisation-in-the-management-of-fibroids/)—clinical recommendations on the use of uterine artery embolisation in the management of fibroids

Resources for patients

- NHS Choices. Fibroids (www.nhs.uk/Conditions/Fibroids/Pages/Introduction.aspx)—evidence based advice on uterine fibroids
- FEMISA. Fibroid embolisation: information, support, advice (www.femisa.org.uk)—information on fibroid embolisation
- British Fibroid Trust. Support (www.britishfibroidtrust.org.uk)—provides general information

How were patients included in the creation of this article?

Having been a patient with fibroids, Ginette Camps-Walsh critically reviewed this manuscript and provided helpful input. She is now a patient advocate, campaigning to raise awareness of alternatives to hysterectomy such as uterine artery embolisation.

Competing interests: We have read and understood the BMJ policy on declaration of interests and declare the following: none.

Patient consent: Obtained.

Provenance and peer review: Commissioned; externally peer reviewed.

- 1 Baird DD, Dunson DB, Hill MC, Cousins D, Schectman JM. High cumulative incidence of uterine leiomyoma in black and white women: ultrasound evidence. *Am J Obstet Gynecol* 2003;188:100-7.
- 2 Gov.UK. Payments by results in the NHS: tariff for 2012-2013. www.gov.uk/government/publications/payment-by-results-pbr-operational-guidance-and-tariffs.
- 3 Ligon AH, Morton CC. Genetics of uterine leiomyomata. *Genes Chromosomes Cancer* 2000;28:235-45.
- 4 D'Aloisio AA, Baird DD, DeRoo LA, Sandler DP. Association of intrauterine and early-life exposures with diagnosis of uterine leiomyomata by 35 years of age in the Sister Study. *Environ Health Perspect* 2010;118:375-81.
- 5 Chen CR, Buck GM, Courey NG, Perez KM, Wactawski-Wende J. Risk factors for uterine fibroids among women undergoing tubal sterilization. *Am J Epidemiol* 2001;153:20-6.
- 6 Wise LA, Palmer JR, Harlow BL, et al. Reproductive factors, hormonal contraception, and risk of uterine leiomyomata in African-American women: a prospective study. *Am J Epidemiol* 2004;159:113-23.
- 7 Ross RK, Pike MC, Vessey MP, et al. Risk factors for uterine fibroids: reduced risk associated with oral contraceptives. *BMJ* 1986;293:359-62.
- 8 Terry KL, De Vivo I, Hankinson SE, et al. Anthropometric characteristics and risk of uterine leiomyoma. *Epidemiology* 2007;18:758-63.
- 9 Moravsek MB, Yin P, Ono M, et al. Ovarian steroids, stem cells and uterine leiomyoma: therapeutic implications. *Hum Reprod Update* 2015;21:1-12.
- 10 Yang CH, Lee JN, Hsu SC, Kuo CH, Tsai EM. Effect of hormone replacement therapy on uterine fibroids in postmenopausal women—a 3-year study. *Maturitas* 2002;43:35-9.
- 11 Mavrelou D, Ben-Nagi J, Holland T, et al. The natural history of fibroids. *Ultrasound Obstet Gynecol* 2010;35:238-42.
- 12 Evans P, Brunsell S. Uterine fibroid tumors: diagnosis and treatment. *Am Fam Physician* 2007;75:1503-8.
- 13 Gupta S, Jose J, Manyonda I. Clinical presentation of fibroids. *Best Pract Res Clin Obstet Gynaecol* 2008;22:615-26.
- 14 Drayer SM, Catherino WH. Prevalence, morbidity, and current medical management of uterine leiomyomas. *Int J Gynaecol Obstet* 2015 published online 5 Aug.
- 15 Shwayder J, Sakhel K. Imaging for uterine myomas and adenomyosis. *J Minim Invasive Gynecol* 2014;21:362-76.
- 16 Vercellini P, Cortesi I, Oldani S, et al. The role of transvaginal ultrasonography and outpatient diagnostic hysteroscopy in the evaluation of patients with menorrhagia. *Hum Reprod* 1997;12:1768-71.
- 17 Seshadri S, El-Toukhy T, Douiri A, Jayaprakasan K, Khalaf Y. Diagnostic accuracy of saline infusion sonography in the evaluation of uterine cavity abnormalities prior to assisted reproductive techniques: a systematic review and meta-analyses. *Hum Reprod Update* 2015;21:262-74.
- 18 Goto A, Takeuchi S, Sugimura K, Maruo T. Usefulness of Gd-DTPA contrast-enhanced dynamic MRI and serum determination of LDH and its isozymes in the differential diagnosis of leiomyosarcoma from degenerated leiomyoma of the uterus. *Int J Gynecol Cancer* 2002;12:354-61.
- 19 Sato K, Yuasa N, Fujita M, Fukushima Y. Clinical application of diffusion-weighted imaging for preoperative differentiation between uterine leiomyoma and leiomyosarcoma. *Am J Obstet Gynecol* 2014;210:368 e1-8.
- 20 Spielmann AL, Keogh C, Forster BB, Martin ML, Machan LS. Comparison of MRI and sonography in the preliminary evaluation for fibroid embolization. *AJR Am J Roentgenol* 2006;187:1499-504.
- 21 Kaump GR, Spiess JB. The impact of uterine artery embolization on ovarian function. *J Vasc Interv Radiol* 2013;24:459-67.
- 22 Lefebvre G, Vilos G, Allaire C, et al. The management of uterine leiomyomas. *J Obstet Gynaecol Can* 2003;25:396-418; quiz 419-22.
- 23 National Institute for Health and Care Excellence. Heavy menstrual bleeding. (Clinical guideline CG44.) 2007. http://guidance.nice.org.uk/CG44.
- 24 Spitz IM. Clinical utility of progesterone receptor modulators and their effect on the endometrium. *Curr Opin Obstet Gynecol* 2009;21:318-24.

- 25 Maruo T, Matsuo H, Samoto T, et al. Effects of progesterone on uterine leiomyoma growth and apoptosis. *Steroids* 2000;65:585-92.
- 26 Donnez J, Tatarchuk TF, Bouchard P, et al. Ulipristal acetate versus placebo for fibroid treatment before surgery. *N Engl J Med* 2012;366:409-20.
- 27 Donnez J, Tomaszewski J, Vázquez F, et al. Ulipristal acetate versus leuprolide acetate for uterine fibroids. *N Engl J Med* 2012;366:421-32.
- 28 National Institute for Health and Care Excellence. Interventional procedure overview of uterine artery embolisation for fibroids. (Interventional procedure guidance IPG367.) 2010. www.nice.org.uk/guidance/ipg367.
- 29 Gupta JK, Sinha A, Lumsden MA, Hickey M. Uterine artery embolization for symptomatic uterine fibroids. *Cochrane Database Syst Rev* 2014;12:CD005073.
- 30 Royal College of Obstetricians and Gynaecologists and Royal College of Radiologists. Clinical recommendations on the use of uterine artery embolisation (UAE) in the management of fibroids. 3rd ed. Dec 2013. RCOG, 2013. www.rcog.org.uk/globalassets/documents/guidelines/23-12-2013_rcog_rcr_uae.pdf.
- 31 LaMotte AI, Lalwani S, Diamond MP. Morbidity associated with abdominal myomectomy. *Obstet Gynecol* 1993;82:897-900.
- 32 Kongnyuy EJ, Wiysonge CS. Interventions to reduce haemorrhage during myomectomy for fibroids. *Cochrane Database Syst Rev* 2014;8:CD005355.
- 33 Metwally M, CheongYC, Horne AW. Surgical treatment of fibroids for subfertility. *Cochrane Database Syst Rev* 2012;11:CD003857.
- 34 Casini ML, Rossi F, Agostini R, Unfer V. Effects of the position of fibroids on fertility. *Gynecol Endocrinol* 2006;22:106-9.
- 35 Palomba S, Zupi E, Falbo A, et al. A multicenter randomized, controlled study comparing laparoscopic versus minilaparotomic myomectomy: reproductive outcomes. *Fertil Steril* 2007;88:933-41.
- 36 Bosteels J, Kasius J, Weyers S, et al. Hysteroscopy for treating subfertility associated with suspected major uterine cavity abnormalities. *Cochrane Database Syst Rev* 2015;2:CD009461.
- 37 Manyonda IT, Bratby M, Horst JS, et al. Uterine artery embolization versus myomectomy: impact on quality of life—results of the FUME (Fibroids of the Uterus: Myomectomy versus Embolization) Trial. *Cardiovasc Intervent Radiol* 2012;35:530-6.
- 38 Sizzi O, Rossetti A, Malzoni M, et al. Italian multicenter study on complications of laparoscopic myomectomy. *J Minim Invasive Gynecol* 2007;14:453-62.
- 39 Dubuisson JB, Fauconnier A, Deffarges JV, et al. Pregnancy outcome and deliveries following laparoscopic myomectomy. *Hum Reprod* 2000;15:869-73.
- 40 Gyamfi-Bannerman C, Gilbert S, Landon MB, et al. Risk of uterine rupture and placenta accreta with prior uterine surgery outside of the lower segment. *Obstet Gynecol* 2012;120:1332-7.
- 41 Varma R, Soneja H, Clark TJ, Gupta JK. Hysteroscopic myomectomy for menorrhagia using Versascope bipolar system: efficacy and prognostic factors at a minimum of one year follow up. *Eur J Obstet Gynecol Reprod Biol* 2009;142:154-9.
- 42 Cano Lopez H, Cano Aguilar HE, Cano Aguilar FD. [Transcervical myomectomy and uterine fibroids: report of ten cases.] *Ginecol Obstet Mex* 2012;80:654-8.
- 43 McPherson K, Metcalfe MA, Herbert A, et al. Severe complications of hysterectomy: the VALUE study. *BJOG* 2004;111:688-94.
- 44 Carranza-Mamane B, Havelock J, Hemmings R, et al. The management of uterine fibroids in women with otherwise unexplained infertility. *J Obstet Gynaecol Can* 2015;37:277-88.
- 45 Laughlin SK, Baird DD, Savitz DA, Herring AH, Hartmann KE. Prevalence of uterine leiomyomas in the first trimester of pregnancy: an ultrasound-screening study. *Obstet Gynecol* 2009;113:630-5.
- 46 Pritts EA, Parker WH, Olive DL. Fibroids and infertility: an updated systematic review of the evidence. *Fertil Steril* 2009;91:1215-23.
- 47 Muram D, Gillieson M, Walters JH. Myomas of the uterus in pregnancy: ultrasonographic follow-up. *Am J Obstet Gynecol* 1980;138:16-9.
- 48 Gupta S, Manyonda IT. Acute complications of fibroids. *Best Pract Res Clin Obstet Gynaecol* 2009;23:609-17.
- 49 Brohi AS, Li L, Andikyan V, et al. Age-stratified risk of unexpected uterine sarcoma following surgery for presumed benign leiomyoma. *Oncologist* 2015;20:433-9.

Cite this as: *BMJ* 2015;351:h4887

© BMJ Publishing Group Ltd 2015

Tables

Table 1 | Treatment options for fibroids

Treatment type	Study details	Advantages	Disadvantages
Medical treatment:			
Tranexamic acid/mefenamic acid	Summary article, ^{w1} randomised controlled trial ^{w2}	Reduced heavy menstrual bleeding in women without uterine fibroids; improves health related quality of life	Efficacy in presence of fibroids is unknown
Levonorgestrel releasing intrauterine system	Retrospective study, ^{w3} prospective comparative study, ^{w4} prospective cohort study, ^{w5} NICE National guideline No 44, 2007	Treatment of choice for heavy menstrual bleeding in absence of fibroids; provides contraception	Evidence of usefulness in presence of fibroids is limited; cannot be used if uterine cavity is distorted by fibroids; high expulsion rate with submucosal fibroids
Selective progesterone receptor modulators	Randomised controlled trial and open label study, ^{w6-w8} review article, ^{w9} randomised controlled trial, ^{w10} clinical report ^{w11}	Reduces heavy menstrual bleeding and shrinks fibroids; does not cause menopausal side effect or bone demineralisation; licensed for preoperative use to shrink fibroids and for intermittent long term use	Can cause unscheduled bleeding in women with submucous fibroids; is associated with endometrial changes that are not yet fully understood
Mifepristone	Meta-analysis, ^{w12} Cochrane systematic review ^{w13}	Can reduce bleeding and pressure symptoms for up to six months; reduces heavy menstrual bleeding and improves fibroid related quality of life	Uncertain effect on fibroid volume
Gonadotrophin releasing hormone agonists	Literature review, ^{w14} Cochrane systematic review ^{w15}	Can be used for 3-6 months presurgery to reduce uterine size, fibroid size, and perioperative blood loss; leads to amenorrhoea and helps correct iron deficiency anaemia; menopausal side effects can be minimised by the use of "add back" hormone replacement therapy	Long term therapy beyond six months can reduce bone density; vasomotor and other menopausal symptoms are common; more commonly initiated in secondary care, although continuation may take place in primary care
Radiological and surgical:			
Uterine artery embolisation	Cochrane systematic review, ^{w16} national guideline, ^{w17} randomised controlled trial, ^{w18} retrospective study, ^{w19} randomised controlled trial, ^{w20} review article, ^{w21} literature review, ^{w22} single centre cohort analysis, ^{w23} randomised controlled trial, ^{w24} randomised controlled trial ^{w25}	Performed under local anaesthesia (no general anaesthetic required); requires overnight stay in hospital; similar success rates and satisfaction rates to surgery; global uterine fibroid treatment; quick recovery; decreases fibroid size and menstrual blood loss; conserves uterus	Post-procedure pain can be severe and variable; alleviation of symptoms can take up to six months; risk of fibroid expulsion; higher rate of early re-intervention compared with surgery; impact on fertility and pregnancy is uncertain
Myomectomy	Retrospective study, ^{w26} literature review, ^{w27} Cambridge University Press, ^{w28} observational study ^{w29}	Conserves uterus; helps resolve bulk symptoms; can also be performed laparoscopically or hysteroscopically	Insufficient evidence regarding role in improving infertility to conclude that it is best treatment; associated with major surgical risks; risk of fibroid regrowth; not a global uterine fibroid treatment; although morcellation of fibroids is possible at laparoscopic myomectomy, there are concerns about this treatment ^{w30}
Hysterectomy	Prospective multicentre study, ^{w31} NA, ^{w32} randomised controlled trial, ^{w33} randomised controlled trial ^{w34}	Well established effective procedure to permanently resolve fibroid symptoms; cost effective with high patient satisfaction rates; vaginal and minimally invasive laparoscopic approach to this procedure is suitable in selected cases; global uterine fibroid treatment and only treatment that prevents recurrence; higher patient satisfaction rates than with uterine artery embolisation	Is associated with procedure related morbidity and mortality, whatever approach is used; higher surgical complication rates when associated with large fibroids; not suitable for women wanting to preserve fertility

Table 2| Summary of evidence on uterine artery embolisation from updated Cochrane review of five randomised controlled trials*

Outcomes	Surgery	Uterine artery embolisation	Statistically significant
Hospital stay	Longer	Shorter	Yes
Recovery of milestones	Later	Sooner	Yes
Symptom control	Good	Good	Yes
Quality of life	Improved	Improved	No
Reintervention	Uncommon	More common	Yes
Cost effectiveness	Cost effective	Initially cheaper but decreases with time owing to higher reintervention rates	No

*For discussion see Gupta et al.²⁹

Figures

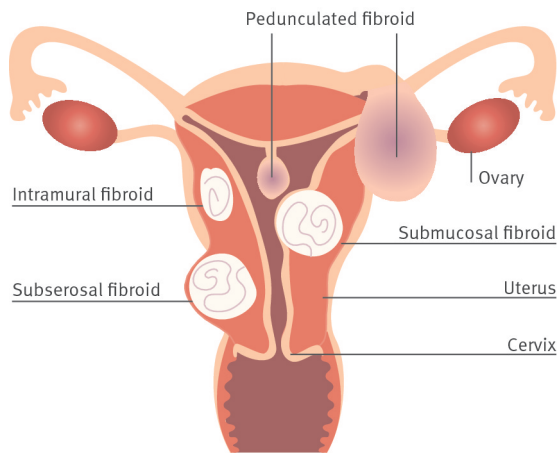


Fig 1 Locations of uterine fibroids. Adapted from Mayo Foundation for medical education (www.mayoclinic.org/diseases-conditions/uterine-fibroids/multimedia/fibroid-locations/img-20006761)

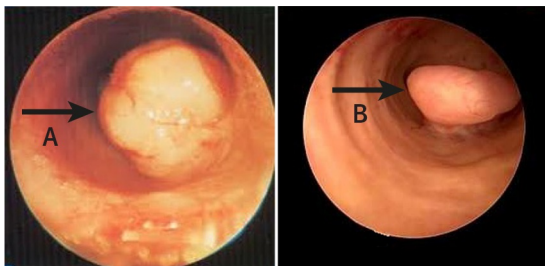


Fig 2 Submucosal fibroid (left) and endometrial polyp (right) visualised on hysteroscopy

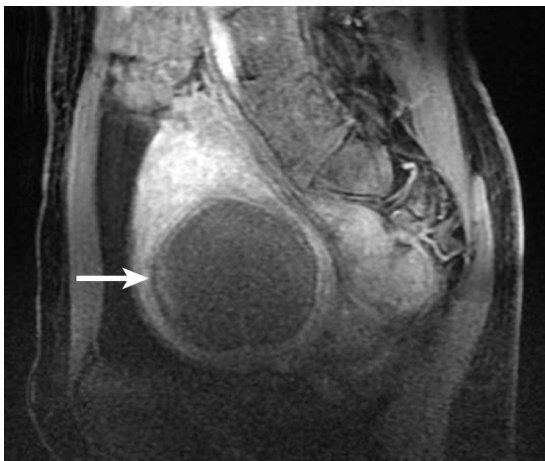

Fig 3 Magnetic resonance imaging showing large non-contrast enhancing uterine fibroid after uterine artery embolisation

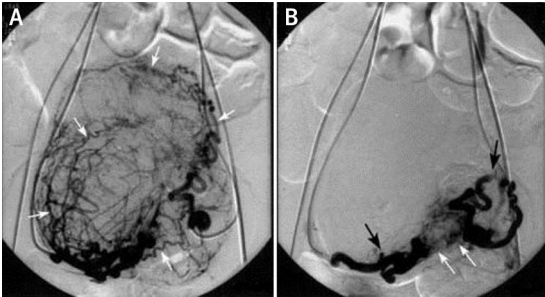


Fig 4 (Left) Fluoroscopy before uterine artery embolisation showing uterine arteries and vessels supplying the fibroid. (Right) Fluoroscopy after uterine artery embolisation showing stasis of uterine arteries. Black arrows indicate uterine arteries, white arrows indicate area of stasis and embolisation agent