

A case of unilateral post-COVID-19 adrenal haemorrhage and follow-up during pregnancies

Mangone, Alessandra; Yousuf, Quratulain; Arlt, Wiebke; Prete, Alessandro; Shaheen, Fozia; Krishnasamy, Senthil-Kumar ; Elhassan, Yasir; Ronchi, Cristina

DOI:
[10.1530/EDM-22-0337](https://doi.org/10.1530/EDM-22-0337)

License:
Creative Commons: Attribution-NonCommercial-NoDerivs (CC BY-NC-ND)

Document Version
Publisher's PDF, also known as Version of record

Citation for published version (Harvard):
Mangone, A, Yousuf, Q, Arlt, W, Prete, A, Shaheen, F, Krishnasamy, S-K, Elhassan, Y & Ronchi, C 2022, 'A case of unilateral post-COVID-19 adrenal haemorrhage and follow-up during pregnancies', *Endocrinology, diabetes & metabolism case reports*, vol. 2022, no. 1, 22-0337. <https://doi.org/10.1530/EDM-22-0337>

[Link to publication on Research at Birmingham portal](#)

General rights

Unless a licence is specified above, all rights (including copyright and moral rights) in this document are retained by the authors and/or the copyright holders. The express permission of the copyright holder must be obtained for any use of this material other than for purposes permitted by law.

- Users may freely distribute the URL that is used to identify this publication.
- Users may download and/or print one copy of the publication from the University of Birmingham research portal for the purpose of private study or non-commercial research.
- User may use extracts from the document in line with the concept of 'fair dealing' under the Copyright, Designs and Patents Act 1988 (?)
- Users may not further distribute the material nor use it for the purposes of commercial gain.

Where a licence is displayed above, please note the terms and conditions of the licence govern your use of this document.

When citing, please reference the published version.

Take down policy

While the University of Birmingham exercises care and attention in making items available there are rare occasions when an item has been uploaded in error or has been deemed to be commercially or otherwise sensitive.

If you believe that this is the case for this document, please contact UBIRA@lists.bham.ac.uk providing details and we will remove access to the work immediately and investigate.

A case of unilateral post-COVID-19 adrenal haemorrhage and follow-up during pregnancies

Alessandra Mangone^{1,2,3}, Quratulain Yousuf⁴, Wiebke Arlt^{3,5}, Alessandro Prete^{3,5}, Fozia Shaheen³, Senthil-kumar Krishnasamy⁶, Yasir S Elhassan^{3,5} and Cristina L Ronchi^{3,5,7}

¹Department of Clinical Sciences and Community Health, University of Milan, Milan, Italy, ²Endocrinology Unit, Fondazione IRCCS Ca' Granda Ospedale Maggiore Policlinico, Milan, Italy, ³Institute of Metabolism and System Research, University of Birmingham, Birmingham, UK, ⁴University Hospitals of North Midlands NHS Trust, Stoke-on-Trent, UK, ⁵Centre for Endocrinology, Diabetes and Metabolism, Birmingham Health Partners, Birmingham, UK, ⁶Walsall Healthcare NHS Trust, Walsall, UK, and ⁷Department of Endocrinology and Diabetes, University Hospital of Wurzburg, Wurzburg, Germany

Correspondence
should be addressed
to C L Ronchi
Email
C.L.Ronchi@bham.ac.uk

Summary

The spectrum of endocrine-related complications of COVID-19 infection is expanding; one of the most concerning of which is adrenal haemorrhage due to the risk of catastrophic adrenal crisis. In this study, we present a case that highlights the challenging management of a large, indeterminate unilateral adrenal mass during pregnancy and draws attention to a rare yet probably underestimated complication of COVID-19. During hospitalization for severe COVID-19 pneumonia, a 26-year-old woman was incidentally found to have a 12.5 cm heterogeneous left adrenal mass. Soon after the discovery, she became pregnant and upon referral, she was in the seventh week of gestation, without clinical or biochemical features of hormonal excess. The uncertainty of the diagnosis and the risks of malignancy and surgical intervention were discussed with the patient, and a period of radiological surveillance was agreed upon. An MRI scan performed 3 months later showed a size reduction of the adrenal lesion to 7.9 cm, which was against malignancy. A Doppler ultrasound showed a non-vascular, well-defined round lesion consistent with an adrenal haematoma, likely a complication of the recent COVID-19 infection. The multidisciplinary team recommended further radiological follow-up. The patient then spontaneously had miscarriage at 12 weeks gestation. Subsequent radiological surveillance showed a further size reduction of the adrenal lesion to 5.5 cm. The patient conceived again during follow-up, and the repeated Doppler ultrasound showed stable appearances of the adrenal mass, and thus, it was agreed to continue radiological monitoring after delivery. The pregnancy was uneventful, and the patient delivered a healthy baby. An MRI scan performed after delivery showed a stable but persistent lesion consistent with a likely underlying adrenal lesion.

Learning points

- Unilateral adrenal haemorrhage can occur as a complication of COVID-19 and should be considered in the differential diagnosis of heterogeneous adrenal masses if there is a history of recent infection.
- Management of large indeterminate adrenal masses during pregnancy poses several challenges and should be led by an experienced multidisciplinary team.
- Underlying adrenal tumours may trigger non-traumatic haemorrhages, especially if exacerbated by stressful illness.

Background

Coronavirus disease 19 (COVID-19) is an infectious disease caused by severe acute respiratory syndrome coronavirus 2 (SARS-CoV-2), which can show a wide spectrum of morbidity, partially linked to the high rate of prothrombotic complications due to the severe pro-inflammatory state. Among the several reports that highlight the endocrine complications of SARS-CoV-2 infection, bilateral (1, 2, 3, 4, 5) and more rarely unilateral (6) adrenal haemorrhage have been reported. Adrenal haemorrhage can be diagnosed incidentally due to the non-specific or even occult clinical presentation.

The number of incidentally discovered adrenal masses is increasing, and adequate diagnostic work-up is necessary, especially in cases of large lesions where, in the suspect of adrenocortical carcinoma (ACC), surgery is indicated (7). Management of large indeterminate adrenal masses detected during pregnancy is particularly complex given the risk of adrenal malignancy and the obstetric maternal and fetal risks of surgical intervention (7, 8, 9).

Here, we report the case of a woman with a large, heterogeneous adrenal mass that presented during pregnancy with an appearance suspicious of adrenal malignancy but was later confirmed as adrenal haemorrhage post-COVID-19 infection.

Case presentation

A 26-year-old female presented in September 2020 at a local hospital with fever, breathlessness, cough, and pleuritic chest pain. She tested positive in a PCR test for SARS-CoV-2 and was hospitalised for severe bilateral pneumonia. A pulmonary embolism was suspected and a CT pulmonary angiogram was performed. The scan excluded a pulmonary embolism but incidentally revealed a large left adrenal mass with heterogeneous density. An abdominal CT scan was arranged to further characterise the mass, which confirmed a left adrenal heterogeneous lesion of at least 12 cm diameter that displaced the adjacent organs and vessels. There was also evidence of fluid density in the tumour with surrounding fat stranding. Mean pre-contrast attenuation was Hounsfield units (HU) 21 (Fig. 1). The initial clinical and hormonal assessment showed no evidence of hormone excess, except for marginally elevated serum testosterone levels (Table 1). The patient was treated with 6 mg of oral dexamethasone daily for COVID-19 pneumonia, which was later discontinued after improvement of respiratory parameters.

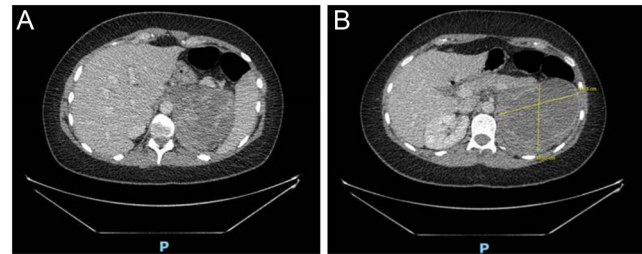


Figure 1

Initial radiological imaging showing a large, indeterminate adrenal lesion. Selected transverse image from abdomen CT scan with contrast in September 2020: left-sided heterogeneous adrenal mass measuring 12.5 × 9.5 cm, with surrounding fat stranding and fluid density, extending in the peri-renal regions and pushing the left kidney and renal vessels inferiorly and the pancreas and splenic vessels anteriorly. The lesion shows pre-contrast attenuation of 21 Hounsfield units with enhancing walls and septae and with nodular and enhancing soft tissue component (75 HU). No local lymph node enlargement. Panel A shows heterogeneity of the adrenal lesion. Panel B shows the maximum diameter of the adrenal lesion. Conclusion: large left adrenal mass most likely suggestive of primary adrenal tumour.

Due to the suspicious presentation of the mass, the patient was referred to our regional tertiary Adrenal Tumour Service at the Queen Elizabeth Hospital Birmingham for further management.

Meanwhile, the patient fully recovered from COVID-19 pneumonia, and soon after hospital discharge, she became pregnant.

Investigation

At the time of the referral to the Adrenal Tumour Clinic at the Queen Elizabeth Hospital Birmingham in November 2020, the patient was 7 weeks pregnant. A clinical examination showed no features of adrenal hormone excess. A full endocrine work-up was performed and indicated no evidence of glucocorticoid, androgen, mineralocorticoid, or catecholamine excess (Table 1). We also performed a 24-h urinary steroid metabolome analysis profile (USM), available in our research centre. This was aimed to identify a potential hormonal signature (steroid precursors and metabolites) suspicious of adrenal malignancy (10, 11). The resulting multi-steroid profile was compared to a control cohort of six healthy pregnant women from the same gestational period (Fig. 2). Details are explained in Fig. 2. Substantially, the USM profile of the patient was not indicative of ACC. Unremarkable full blood count, C-reactive protein, and lactate dehydrogenase were against lymphoma.

The case was discussed at the local multidisciplinary team (MDT) meeting. Because of the low likelihood



Table 1 Biochemical and hormonal investigations at the time of the diagnosis. During the first assessment, the patient was still on corticosteroid medications for COVID-19 pneumonia, and thus, screening for hypercortisolism was not performed.

Test	Value	Reference range
September 2020 (while on dexamethasone for COVID-19)		
Testosterone, nmol/L	1.74	0.29–1.67
DHEAS, µmol/L	7.7	2.6–13.9
Aldosterone, pmol/L	172	
Renin, mU/L	50.7	
Aldosterone to renin ratio	3.4	0–31
24-h urinary catecholamines	Normal	
Normetadrenaline, µmol/24 h	1.77	0.89–2.88
3-Methoxytyramine, µmol/24 h	1.11	0.57–2.39
November 2020 (when 7-week pregnant)		
24-h urinary-free cortisol, nmol/24 h	75	<130
Overnight DST, nmol/L	<50	<50
Testosterone, nmol/L	1.5	<1.9*
DHEAS, µmol/L	3.75	2.6–13.9*
Androstenedione, nmol/L	5.5	0.9–7.5*
Plasma normetadrenaline, pmol/L	<600	<730
Plasma metadrenaline, pmol/L	<200	<450
Plasma 3-methoxytyramine, pmol/L	<200	<180
ACTH, ng/L	19	0–50
Morning cortisol, nmol/L	209	172–497
Short synacthen test		
Basal cortisol, nmol/L	530	Adequate response
30 min cortisol, nmol/L	815	>550
C-reactive protein, mg/L	7	0–5
LDH, U/L	142	125–220

*Normal values in women in follicular phase.
DST, dexamethasone suppression test.

of adrenal malignancy based on normal serum adrenocortical hormones and USM and the obstetric risks of surgical intervention to the mother and fetus, it was agreed with the patient to undertake a conservative approach with short-term interval imaging during pregnancy.

An MRI scan without contrast performed 3 months after the initial CT surprisingly showed a reduction in the size of the adrenal lesion from 12 to 7.6 cm, with mostly reduction of the fluid component but a persistent mass effect (Fig. 3A). At that point, a complex haematoma was considered in the differential diagnosis. Due to the recent medical history, a possible COVID-19-related adrenal haematoma was suspected. The MDT recommended an urgent Doppler ultrasound, which showed that the lesion was nonvascular and well-defined, thus supporting the likelihood of haematoma (Fig. 3B). Therefore, further radiological surveillance was recommended. A short synacthen test showed adequate cortisol response, thus ruling out adrenal insufficiency, which can rarely occur even in the setting of a unilateral infarction (12). Unfortunately, the patient had a spontaneous miscarriage at 12 weeks of gestation.

Outcome and follow-up

A surveillance MRI scan with contrast was performed 3 months later, which showed further size reduction to 5.5 cm, but persistent capsular thickening and enhancing internal components (Fig. 4C), and hence, the possibility of an underlying left adrenal lesion could not be excluded.

In June 2021, the patient was again pregnant. A repeated Doppler ultrasound at 5 weeks of gestation showed a stable adrenal mass (5.3 cm), which appeared heterogeneous and avascular. The MDT decided not to perform further investigations during pregnancy but to continue radiological monitoring after delivery for surveillance purposes. The pregnancy was uneventful, and the patient delivered a healthy baby boy at term. MRI scan with contrast performed in April 2022 after delivery showed a stable but persistent 5.1 cm lesion with heterogeneous signal intensity and evidence of prior haemorrhage, consistent with an underlying adrenal nodule (Fig. 4D).

Discussion

With the widespread use of imaging techniques, healthcare professionals are confronted with an increasingly vast

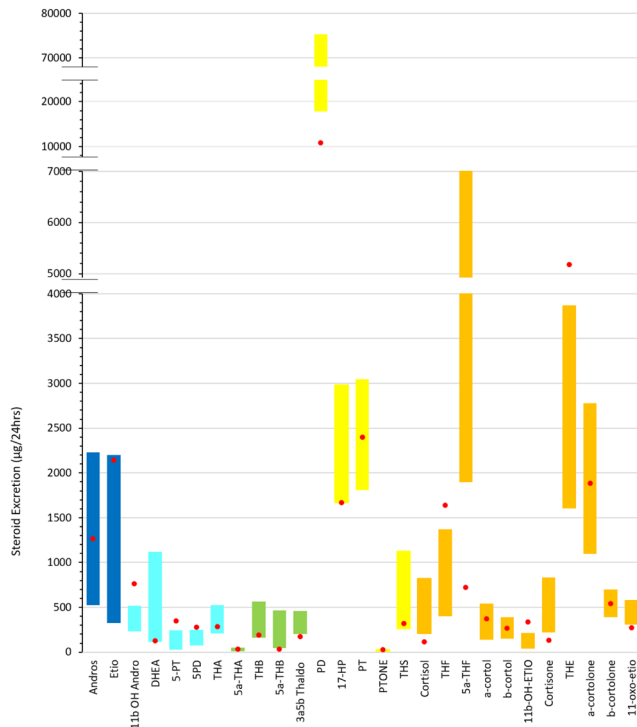


Figure 2

24 h urine steroid metabolome (USM) pattern at time of presentation. The bar chart represents the 24 h urine steroid metabolome profile of the patient (red dots) performed in December 2020 at the University of Birmingham. All hormonal metabolites are expressed in $\mu\text{g}/24\text{ h}$. The patient's profile was compared to six healthy control pregnancy profiles from the same gestational period (represented as bars). The top of the bars represents the upper limit (highest excretion value) and the bottom of the bars represents the lower limit (lowest excretion value) of the control pregnancy reference range. The top urinary steroid ACC markers as per Arlt *et al.* (10) are tetrahydrocortisol (THS), pregnenetriol (5-PT), pregnenediol (5-PD), pregnanetriol (PT), 5- α -tetrahydro-11dehydro-corticosterone (5- α -THA), etiocholanolone (ET), 5- α -tetrahydrocortisol (5- α -THF), and pregnenediol (PD). This 24-h urinary steroid profile, when compared to six healthy control pregnancy excretion values from the same gestational period, does not indicate signs of abnormal steroid excretion indicative of ACC.

number of incidentally discovered adrenal masses. ACC is a rare malignancy but accounts for up to 5% of adrenal incidentalomas (11). It generally presents a highly aggressive behaviour and surgical removal is the treatment of choice. Therefore, an accurate diagnostic work-up is required to differentiate benign from malignant adrenal lesions, as recommended by current guidelines (13). As a first step, imaging provides guidance, especially when consistent with benign appearance (i.e. homogeneous, $\text{HU} \leq 10$ at non-contrast CT scan, size $\leq 4\text{ cm}$) (13). In this case, the lesion initially presented sinister features on CT scan, being large, heterogeneous, lipid-poor, and causing mass effect and inflammation of surrounding tissues. To further assess for primary adrenal malignancy, USM profile

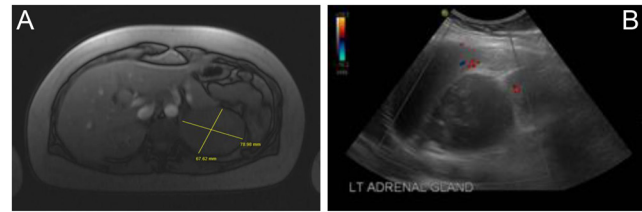


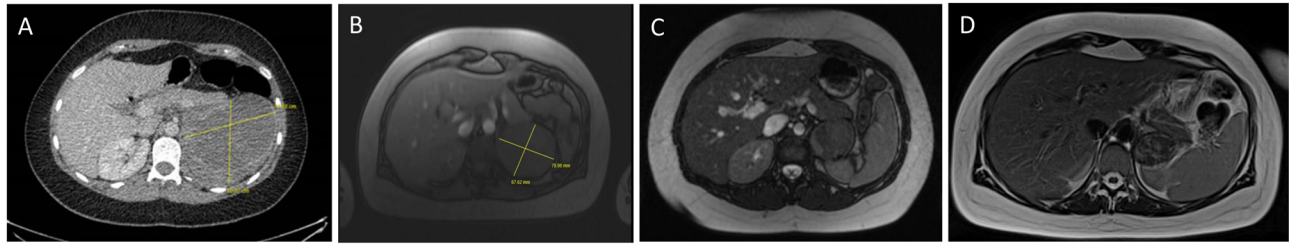
Figure 3

Interval radiological imaging suggesting the presence of post-haemorrhage changes. (A) MRI scan without contrast in December 2020: reduction in the size of the heterogeneous left adrenal mass, now measuring $7.5 \times 7.9 \times 7.5\text{ cm}$, with no loss of signal on out-of-phase imaging. The previously seen surrounding free fluid significantly reduced in size with an evident reduction in the cystic component. The adrenal lesion causes a mass effect on the upper pole of the left kidney, with no evidence of invasion. The appearances are most in keeping with a primary adrenal malignancy, but the radiologist specifies that 'contrast would have been useful to confirm the presence of enhancing components as a less likely differential would include a haematoma'. (B) Doppler ultrasound in December 2020: known mass in left adrenal gland measuring $6.4 \times 6.9 \times 7.1\text{ cm}$ and appearing as nonvascular, well-defined, and solid with a heterogenous texture but a relatively smooth outline suggestive of post-haemorrhage changes.

was performed. This is a noninvasive technique which can accurately identify ACC (10, 11). USM did not reveal a steroid signature of ACC.

The unexpected reduction in the size of the adrenal lesion at the repeated scan flagged adrenal haematoma in the differential diagnosis, particularly in the setting of a recent severe SARS-CoV-2 infection. Literature on both endocrine-related and prothrombotic complications of COVID-19 is continuing to expand, underlying the importance of considering its many and complex implications. Among all organ manifestations, the degeneration and necrosis of the adrenal gland are reported as one of the most relevant endocrine manifestations (14). This has been linked to the hypercoagulable state of the infection united with the susceptibility of adrenal glands to infarction and haemorrhage due to their vascular anatomy, characterised by abundant arterial supply yet limited venous drainage. Moreover, both receptors ACE2 and serine protease TMPRSS2 are found widely expressed in the adrenal gland, suggesting that the adrenal cortex may be also a direct target organ of SARS-CoV-2, as described for other coronaviruses (15).

A few reports of acute adrenal infarction in SARS-CoV-2-positive patients have been published. To date, we identified six cases (1, 2, 3, 4, 5, 6), with two of them found to have an underlying hypercoagulable state (antiphospholipid antibody syndrome) (1, 3). Most articles (1, 2, 3, 4, 5) described bilateral adrenal haemorrhage associated with primary adrenal insufficiency. The importance of this entity relies on its potentially fatal

**Figure 4**

Surveillance radiological imaging showing an underlying adrenal lesion. Comparison of axial images of the adrenal mass from the CT scan at diagnosis of September 2020 (A) to the MRI in December 2020 (B), March 2021 (C), and April 2022 (D) shows a progressive reduction in diameters. MRI scan with contrast of March 2021 (C): known left adrenal mass measuring 5.5 cm × 5.4 cm, largely low/isointense on both T1 and T2 sequences, but with some areas of internal T2 hyperintensity possibly related to septations. Evidence of internal fat was suggested by circumferential capsular enhancement following gadolinium administration with focal capsular thickening in the medial aspect and no significant signal dropout on opposed-phase imaging. Last MRI scan with contrast in April 2022 (D): adrenal mass slightly further reduced in size, measuring 5.1 × 3.8 × 3.5 cm, with persistent heterogeneous signal intensity and evidence of prior haemorrhage, further confirming the possibility of an underlying lesion.

consequences, as adrenal insufficiency is life-threatening if not identified and treated promptly. Sharrak and colleagues (6), however, reported the case of a 53-year-old male with a unilateral large and heterogeneous adrenal mass representing an adrenal hematoma as a complication of COVID-19 in the absence of abdominal symptoms or clinical signs of adrenal insufficiency. The patient showed both radiological imaging and clinical presentation similar to our case, he made full recovery, and after 5 months, the haematoma was nearly reabsorbed. In our case, on the contrary, the left heterogeneous adrenal mass has only partially reduced in size after 19 months of surveillance, and its maximum diameter remains above 4 cm. Hence, considering the young age of the patient (26 years), this mass is worth of careful radiological surveillance. Although no older imaging was available, we believe that most likely our patient has a pre-existing adrenal tumour, which bled during the SARS-CoV-2 infection. In fact, underlying lesions may act as triggers for non-traumatic haemorrhages, especially if exacerbated by a stressful illness (16). For this reason, we suggest maintaining a 6- to 9-month radiological follow-up to ensure the haematoma is reabsorbed and/or the lesion remains stable in its appearance and features. Moreover, although adrenal insufficiency mainly occurs in patients with bilateral haemorrhage, previous reports have described hypoadrenalism occurring in the setting of a unilateral infarction (12), likely suggesting microinfarction in the contralateral adrenal gland. Hence, it is important to be alert to this possibility and baseline or dynamic cortisol assessment should still be undertaken if there is suspicion of adrenal insufficiency.

This case was particularly challenging due to the ongoing gestation. When an adrenal mass is suspected to be malignant, adrenalectomy is recommended regardless of pregnancy trimester (7). Nevertheless,

surgical intervention carries a significant risk of maternal and even more fetal complications (i.e. premature birth, intrauterine growth retardation, intrauterine fetal death, miscarriage), especially when indicated for malignant lesions (8, 9).

Our patient was not yet pregnant when the mass was first discovered, so pregnancy as a cause of the bleeding could be ruled out. This is important, as pregnancy is known to be an important risk factor for thrombosis and cases of spontaneous adrenal haemorrhage during otherwise uncomplicated pregnancies have rarely been described (16). Nevertheless, literature on management during gestation has proven to be of use as it recommends a conservative approach in clinically stable patients, suggesting radiological surveillance to confirm the stability or resolution of the hematoma (16).

Conclusion

Unilateral adrenal haemorrhage has been reported following COVID-19, and hence, in the presence of a history of a recent infection, it should be considered in the differential diagnosis of a large heterogeneous adrenal mass, even when discovered incidentally. Herein, management was further complicated by pregnancy. In this complex setting, the multidisciplinary team guided the patient's management and inappropriate adrenal surgery was avoided. We, therefore, suggest that challenging cases should be referred to experienced adrenal centres for the best clinical outcome.

Declaration of interest

The authors declare that there is no conflict of interest that could be perceived as prejudicing the impartiality of the research reported.



Funding

This work did not receive any specific grant from any funding agency in the public, commercial, or not-for-profit sector.

Ethical approval statement

Not applicable, because this article (case report) does not contain any studies with human or animal subjects. Clinical management and monitoring were part of standard clinical care and hence ethical approval was not required.

Patient consent

The patient provided written informed consent for publication of the submitted article and accompanying deidentified images.

Author contribution statement

All authors contributed to the conception and editing of the manuscript. AM, QY, and CR wrote the initial draft of the article, co-ordinated with the other authors and prepared the final manuscript. QY, SK, MA, YE, and CR contributed to clinical care of the patient. FS processed the USM sample and analysed the data; AP and WA provided expert opinion on the results. All authors revised the manuscript and accepted the final version.

Acknowledgements

The authors thank the entire adrenal multidisciplinary team in our Institution for the support in the management of this complex case, including endocrinologists, radiologists, surgeons, nurses, oncologist, and pathologists. The authors also thank our adrenal specialist nurse Miriam Asia for excellent patient care.

References

- 1 Frankel M, Feldman I, Levine M, Frank Y, Bogot NR, Benjaminov O, Kurd R, Breuer GS & Munter G. Bilateral adrenal hemorrhage in coronavirus disease 2019 patient: a case report. *Journal of Clinical Endocrinology and Metabolism* 2020 **105** 1–5. (<https://doi.org/10.1210/clinem/dgaa487>)
- 2 Elkhoully MMN, Elazzab AA & Moghul SS. Bilateral adrenal hemorrhage in a man with severe COVID-19 pneumonia. *Radiology Case Reports* 2021 **16** 1438–1442. (<https://doi.org/10.1016/j.radcr.2021.03.032>)
- 3 Machado IFR, Menezes IQ, Figueiredo SR, Coelho FMA, Terrabuio DRB, Ramos DV, Fagundes GFC, Maciel AAW, Latronico AC, Fragoso MCBV, et al. Primary adrenal insufficiency due to bilateral adrenal infarction in COVID-19. *Journal of Clinical Endocrinology and Metabolism* 2021 **107** e394–e400. (<https://doi.org/10.1210/clinem/dgab557>)
- 4 Kumar R, Guruparan T, Siddiqi S, Sheth R, Jacyna M, Naghibi M & Vrentzou E. A case of adrenal infarction in a patient with COVID 19 infection. *BJR Case Reports* 2020 **6** 20200075. (<https://doi.org/10.1259/bjrcr.20200075>)
- 5 Álvarez-Troncoso J, Zapatero Larrauri M, Montero Vega MD, Gil Vallano R, Palmier Peláez E, Martín Rojas-Marcos P, Martín-Luengo F, Lázaro Del Campo P, Herrero Gil CR & Trigo Esteban E. Case report: COVID-19 with bilateral adrenal hemorrhage. *American Journal of Tropical Medicine and Hygiene* 2020 **103** 1156–1157. (<https://doi.org/10.4269/ajtmh.20-0722>)
- 6 Sharrack N, Baxter CT, Paddock M & Uchegbu E. Adrenal haemorrhage as a complication of COVID-19 infection. *BMJ Case Reports* 2020 **13** 5–8. (<https://doi.org/10.1136/bcr-2020-239643>)
- 7 Fassnacht M, Dekkers OM, Else T, Baudin E, Berruti A, de Krijger R, Haak HR, Mihai R, Assie G & Terzolo M. European Society of Endocrinology Clinical Practice Guidelines on the management of adrenocortical carcinoma in adults, in collaboration with the European Network for the Study of Adrenal Tumors. *European Journal of Endocrinology* 2018 **179** G1–G46. (<https://doi.org/10.1530/EJE-18-0608>)
- 8 Gaujoux S, Hain É, Marcellin L, de Carbonnieres A, Goffinet F, Bertherat J & Dousset B. Adrenalectomy during pregnancy: a 15-year experience at a tertiary referral center. *Surgery* 2020 **168** 335–339. (<https://doi.org/10.1016/j.surg.2020.03.019>)
- 9 Jairath A & Aulakh BS. Adrenocortical carcinoma in pregnancy: a diagnostic dilemma. *Indian Journal of Urology* 2014 **30** 342–344. (<https://doi.org/10.4103/0970-1591.128507>)
- 10 Arlt W, Biehl M, Taylor AE, Hahner S, Libé R, Hughes BA, Schneider P, Smith DJ, Stiekema H, Krone N, et al. Urine steroid metabolomics as a biomarker tool for detecting malignancy in adrenal tumors. *Journal of Clinical Endocrinology and Metabolism* 2011 **96** 3775–3784. (<https://doi.org/10.1210/jc.2011-1565>)
- 11 Bancos I, Taylor AE, Chortis V, Sitch AJ, Jenkinson C, Davidge-Pitts CJ, Lang K, Tsagarakis S, Macech M, Riester A, et al. Urine steroid metabolomics for the differential diagnosis of adrenal incidentalomas in the EURINE-ACT study: a prospective test validation study. *Lancet Diabetes and Endocrinology* 2020 **8** 773–781. ([https://doi.org/10.1016/S2213-8587\(20\)30218-7](https://doi.org/10.1016/S2213-8587(20)30218-7))
- 12 Ly BA & Quintero L. Adrenal Insufficiency from Unilateral Adrenal Hemorrhage in a Patient on Rivaroxaban Thromboprophylaxis. *AACE Clinical Case Reports* 2019 **5** e70–e72. (<https://doi.org/10.4158/ACCR-2018-0340>)
- 13 Fassnacht M, Arlt W, Bancos I, Dralle H, Newell-Price J, Sahdev A, Tabarin A, Terzolo M, Tsagarakis S & Dekkers OM. Management of adrenal incidentalomas: European Society of Endocrinology Clinical Practice Guideline in collaboration with the European Network for the Study of Adrenal Tumors. *European Journal of Endocrinology* 2016 **175** G1–G34. (<https://doi.org/10.1530/EJE-16-0467>)
- 14 Leyendecker P, Ritter S, Riou M, Wackenthaler A, Meziani F, Roy C & Ohana M. Acute adrenal infarction as an incidental CT finding and a potential prognosis factor in severe SARS-CoV-2 infection: a retrospective cohort analysis on 219 patients. *European Radiology* 2021 **31** 895–900. (<https://doi.org/10.1007/s00330-020-07226-5>)
- 15 Mao Y, Xu B, Guan W, Xu D, Li F, Ren R, Zhu X, Gao Y & Jiang L. The adrenal cortex, an underestimated site of SARS-CoV-2 infection. *Frontiers in Endocrinology (Lausanne)* 2021 **11** 1–10. (<https://doi.org/10.3389/fendo.2020.593179>)
- 16 Badawy M, Gaballah AH, Ganeshan D, Abdelalziz A, Remer EM, Alsabbagh M, Westphalen A, Siddiqui MA, Taffel MT, Itani M, et al. Adrenal hemorrhage and hemorrhagic masses; diagnostic workup and imaging findings. *British Journal of Radiology* 2021 **94** 20210753. (<https://doi.org/10.1259/bjr.20210753>)

Received 28 July 2022

Received in final form 25 October 2022

Accepted 6 December 2022