Periodontal health, neutrophil activity and cardiovascular health in captive chimpanzees

Raindi, Devan; Rees, Jacqueline; Hirschfeld, Josefine; Wright, Helen; Dobbs, Phillipa; Moittie, Sophie; White, Kate; Stahl, Wilhelm; Martin, Mike; Redrobe, Sharon; Hughes, Francis; Liptovszky, Matyas; Baiker, Kerstin; Grant, Melissa

DOI:
10.1016/j.archoralbio.2021.105342

Title: Periodontal health, neutrophil activity and cardiovascular health in captive chimpanzees

Authors: Devan Raindi[a], Jaqui Rees[a], Josefine Hirschfeld[a], Helen Wright[a], Phillipa Dobbs[b], Sophie Moittié[b,c], Kate White[c], Wilhelm Stahl[d], Mike Martin[e], Sharon Redrobe[b], Francis Hughes[f], Matyas Liptovszky[b,g], Kerstin Baiker[c], Melissa Grant[a*]

Affiliations

[a] School of Dentistry, Institute of Clinical Sciences, University of Birmingham and Birmingham Dental Hospital, 5 Mill Pool Way, Edgbaston, Birmingham, B5 7EG, UK

[b] Veterinary Department, Twycross Zoo, East Midland Zoological Society, Burton road, Atherstone, CV9 3PX, UK

[c] School of Veterinary Medicine and Science, university of Nottingham, Sutton Bonington, LE12 5RD, UK

[d] Institute of Biochemistry and Molecular Biology I, Medical Faculty, Heinrich Heine University Düsseldorf, D-40001 Düsseldorf, Germany

[e] Veterinary Cardiology Consultancy, Kenilworth, Warwickshire. UK

[f] Kings College London, Guy's Tower, Guy's Hospital, Great Maze Pond, London, SE1 1UL

[g] Current address: Life Sciences Division, Perth Zoo, 20 Labouchere road, South Perth, 6051, WA, Australia

Key words: chimpanzee, periodontitis, cardiac health

[*] Corresponding author

Melissa Grant

School of Dentistry, Institute of Clinical Sciences, University of Birmingham and Birmingham Dental Hospital, 5 Mill Pool Way, Edgbaston, Birmingham, B5 7EG, UK

m.m.grant@bham.ac.uk

Tel 0121 466 5520

Declarations of interest: none

Abstract

Objective: To investigate the association of dental and cardiac disease in a cohort of captive chimpanzees

Design: 12 captive chimpanzees underwent periodontal and cardiac examinations under anaesthesia during a relocation to a new enclosure. Blood samples were taken for analysis of circulating markers of cardiac health, nutritional status and isolation of neutrophils for functional assays. They were then observed for three years for signs of heart disease.

Results: Although the chimpanzees displayed large quantities of supragingival plaque, they had low bleeding scores. Peripheral blood neutrophils responded to innate and adaptive immune stimuli. In the follow up period two animals died and post mortem confirmed heart disease. Levels of NT-proBNP were found to be high in chimpanzees that died from heart disease.

Conclusions: Whilst there appeared to be a correlation between probing depth and age, there appeared to be no correlation between dental data and heart data in this cohort.

Abbreviations

CI chemotactic index

CVD cardiovascular disease

EF% Ejection fraction percentage

FMLP N-formyl-L-methionyl-L-leucyl-phenylalanine

FN *Fusobacterium nucleatum*

GCF gingival crevicular fluid

HOCl hypochlorous acid

IVS long S interventricular septum

LVDd end-diastolic diameter

LVDs end-systolic diameter

LVEDV MOD A4C Left ventricular end-diastolic volume

LVESV MOD A4C Left ventricular end-systolic volume

LVEF MOD A4C Left ventricular ejection fraction

LVFW long S Left ventricular free wall

NT-proBNP N-terminal pro-brain natriuretic peptide

OpsSA opsonised *Staphylococcus aureus*

PBS phosphate buffered saline

PESA Periodontal Epithelial Surface Area

PISA Periodontal Inflamed Surface Area

PMA Phorbol 12-myristate 13-acetate

ROS reactive oxygen species

1. Introduction

Great apes (bonobos, chimpanzees, gorillas and orangutans) are threatened with extinction and therefore it is essential to maintain a self-sustaining zoo population and that requires clinicians to understand how best to maintain health in these animals to maximise life expectancy. A systematic review by (Strong et al., 2016) examining reported morbidity and mortality studies, case studies and single disease prevalence studies between 1990-2014 for all four great apes highlights that cardiovascular and other chronic or age-related diseases are of particular importance for captive ape health. When examining chimpanzees, in particular, cardiovascular disease (CVD) was reported in four morbidity-mortality reviews (Lammey et al., 2008; Munson & Montali, 1990; Nunamaker et al., 2012) with a prevalence of between 11 and 81%. There are extensive efforts internationally to further understand cardiovascular disease (CVD) in great apes: the Ape Heart Project (centred at Twycross Zoo, UK) and the Great Ape Heart Project (centred at Zoo Atlanta, USA). In captive apes, CVD at post mortem is characterised by idiopathic myocardial fibrosis and cardiomyopathy (Strong et al., 2020).

The dentition of *Pan troglodytes* (chimpanzees) is remarkably similar to human dentition with the same permanent tooth set up – namely 2 incisors, 1 canine, 2 premolars and 3 molars per quadrant. Dental attrition (tooth wear), periodontitis and tooth loss are prevalent in ageing great apes (Lowenstine et al., 2016). Studies in the 1970s (Arnold & Baram, 1973; Page et al., 1975) investigated periodontal health in chimpanzees and suggest that there are age-related bone loss and increases in probing pocket depth. This is similar to measures observed in humans. Periodontitis, in particular, is of interest, as in humans this disease is independently and significantly associated with CVD (Tonetti et al., 2013). Indeed, periodontitis is the most common non-communicable inflammatory disease of humans, affecting 60% of over 65-year-olds (Eke et al., 2016). The Association of Zoos and Aquariums recommend close monitoring of chimpanzees for development of periodontal disease (TAG, 2010). However, as yet, no large systematic studies of oral pathology in apes have been published.

Common risk factors for cardiovascular mortality and periodontal disease in humans include pro-inflammatory diets, micronutrient deficiency and sedentary lifestyles. Periodontitis induces a dysregulation of peripheral blood neutrophil (PBN) behaviour leading to hyper-activity and –reactivity (Ling et al., 2015; Matthews et al., 2007) and evidence of oxidative damage in blood and tissues. Neutrophils isolated from an adult male gorilla with localized periodontitis displayed depressed chemotaxis (Lowenstine et al., 2016), as reported in humans (Roberts et al., 2015). Furthermore, neutrophil degranulation has been implicated in the development of fibrotic heart

disease by modification of the cardiac extracellular matrix. Research on fibrotic CVD in humans has reported that neutrophil derived proteins appear to be key players in the initiation of cardiac inflammation and fibrosis (Wu et al., 2014).

. In this study 12 chimpanzees were examined for heart, oral and neutrophil health to observe the occurrence of two prevalent diseases and a potentially contributing cell type across a cohort spanning the life course. Further data gained after the death of two of the animals has allowed for stratification by heart disease in this cohort.

2. Methods

2.1 Chimpanzees

During this cohort study, 12 chimpanzees (*Pan troglodytes*) were followed for three years. In the initial assessment the animals were anaesthetised to allow for safe transfer into a new enclosure at Twycross Zoo, UK in April 2018. This provided an ideal opportunity to assess their cardiac and oral health status without additional anaesthetic burden. This study was approved by the ethics committee of the School of Veterinary Medicine and Science, University of Nottingham (1843 160905).

All chimpanzees were offered midazolam (Hypnovel, Roche, UK) orally (intended dose 0.5mg/kg) although two animals refused to take it. Anaesthesia was induced 30 minutes later with intramuscular (IM) medetomidine 0.02mg/kg (Kyron Prescriptions, South Africa) and tiletamine-zolazepam 2mg/kg (Zoletil 100, Virbac, UK) via hand-injection, except one elderly animal that received tiletamine-zolazepam (3.5 mg/kg) only. Ten minutes after induction of anaesthesia, animals were transported in a crate to the new enclosure, weighed and positioned in dorsal recumbency. The trachea was intubated and anaesthesia was maintained with isoflurane in 100% oxygen via a circle breathing system.

Continuous monitoring commenced once the animals were positioned for the health check and the parameters were recorded at 5-minute intervals. A multifunction veterinary monitor continuously monitored heart rate rhythm, respiratory rate, haemoglobin oxygen saturation using pulse oximetry, end-tidal carbon dioxide partial pressure, oesophageal temperature, end tidal isoflurane, invasive and non-invasive blood pressure. Eye position, palpebral reflex, jaw tone, muscle relaxation, spontaneous movement were also monitored. A comprehensive physical examination was performed on each chimpanzee. In addition, venous blood samples were collected from the femoral vein for haematology and biochemistry; Vacutainer lithium heparin (17 IU/ml) tubes were used for neutrophil isolation and into Vacutainer Serum tubes for serum isolation. Arterial samples were obtained for blood gas analysis. Thoracic, abdominal and limb radiographs were taken, 12-lead ECG and echocardiographic examination, using a GE Vivid i ultrasound machine with a 3MHx probe, as per a previously published protocol (https://twycrosszoo.org/wp-content/uploads/2018/05/C2-Standardised-echo-protocol.pdf) were performed by a trained and experienced veterinary cardiologist (MM). On completion of the procedure, the animals were administered flumazenil 0.2 mg/kg IV and atipamezole 0.1 mg/kg IM. Recovery was monitored until the animals were ambulatory.

2.2 Dental evaluation

All chimpanzees available for assessment were included within the study. GCF was collected prior to any clinical measures, utilising previously standardized techniques prior to probing the sulcus *vide infra* (Chapple et al., 1994). Clinical measurements and GCF sampling were carried out by a single calibrated dentist (DR).

Following charting of teeth present, a detailed periodontal pocket chart was completed recording probing pocket depths and recession at six points per tooth (mesio-buccal, mid-buccal, distal-buccal, mesial-lingual, mid-lingual, distal-lingual) using a University of North Carolina (UNC-15, Hu-Friedy) manual probe aiming for 0.2N force. Following probing, bleeding on probing (BOP) was assessed from the base of crevice using dichotomous measurement. Plaque accumulation was assessed visually, without the use of disclosing dye, and with a probe at the gingival margin, utilising a dichotomous scoring method to then allow conversion to a percentage plaque score as described in the literature (O'Leary et al., 1972). Plaque was collected after all other indices had been assessed. The Periodontal Inflamed Surface Area (PISA) was calculated using the probing pocket depths and bleeding scores as described in the literature (Nesse et al., 2008). Data was inputted into the spreadsheets available at www.parsprototo.info to calculate the Periodontal Epithelial Surface Area (PESA) and subsequently the PISA. Both supragingival and subgingival plaque samples were taken using a curette and clinical photography of the dentition was also carried out.

2.3 Post mortem cardiac examination

For the two animals that died after the relocation, post mortem cardiac exam was performed. Hearts were fully submerged in 10% neutral buffered formalin for at least 72 hours prior to examination and sampling. Formalin fixed entire hearts underwent detailed macroscopic examination and sampling according to a protocol that has been published for use in great apes (Strong et al., 2018). A minimum of twelve cardiac samples were taken from pre-determined and consistent locations including myocardium from the anterior, posterior and lateral left and right ventricular walls, anterior and posterior portions of the interventricular septal wall and right ventricular outflow tract. Samples of the aorta, sino-atrial nodal region and atrioventricular nodal region were also taken. Additional tissue samples of anomalies or lesions detected as part of the

examination were taken as indicated. Histologic sections were prepared from formalin-fixed paraffin-embedded blocks and routinely stained with hematoxylin and eosin (n=2)

2.4 Collection of GCF

The examiner (DR) used portable 3-in-1 unit to dry the area prior to sampling and was precalibrated in taking GCF samples on humans in a calibration session at the Birmingham Dental Hospital. GCF was collected from the UR2, UR5, UR6 and UL2, UL5, UL6 using a PerioPaper strip (PerioPaper, Oraflow Inc., Plainview, USA) placed into the gingival crevice until resistance was felt and left in situ for 30 seconds. GCF volume was ascertained using a pre-calibrated Periotron 8000 (Oraflow Inc., Plain-view, USA) as described previously (Chapple et al., 1999). In the case of an absence of any of the aforementioned teeth the more mesial tooth was selected for sampling. Samples were then eluted into 50µl of phosphate buffered saline (PBS) and stored at -80°C until further analysis.

2.5 Determination of GCF cytokines

A ProcartaPlex ImmunoAssay Kit (ProcartaPlex Multiplex Immunoassay, ThermoFisher Scientific) was used for the detection of non-human primate IL-1β, IL-6, IL-8, IL-17 and TNF-α. The assay protocol was performed following the manufacturer's instructions. The plate was then run on a Luminex 200 and the data analysed.

2.6 Serum measurements

Serum was used to measure NT-proBNP, troponin, fructosamine, HbA1c and Vitamin D (25-hydroxyvitamin D). Vitamin D was measured in serum as previously described by (Moittie et al., 2020) at Laboratory Medicine-Central Manchester University Hospitals. Troponin I and NT-proBNP concentrations were measured using chemiluminescent microparticle immunoassays: Architect High-Sensitivity Troponin I assay and the Alere Abbott NT proBNP assay, using the Architect iSR2000-system (Abbott, Maidenhead, UK).

2.7 Determination of Micronutrient Concentration

Blood samples were stored at -80°C and analyzed for carotenoids and vitamins A and E according to (Stahl et al., 1993). Lutein, zeaxanthin, β-cryptoxanthin, lycopene, and α- and β-carotene were extracted and analyzed by HPLC with UV/vis detection at 450 nm. A second UV/vis detector was set at 325 and 292 nm for quantitation of retinol (vitamin A), and α- and γ-tocopherol (vitamin E), respectively. Recovery from the column was 90% for each analyte. Calibration curves were linear from 0 to 1000 nmol/l for all carotenoids, with correlation coefficients 0.99. The intra- and inter-assay precision was between 5 and 15 %.

2.8 Neutrophil isolation & assays

As it has already been recognised that neutrophils from chimpanzees are morphologically indistinguishable from those of humans (Martin et al., 2011), established methods for human neutrophil isolation were used. Neutrophils were isolated as previously described (Roberts et al., 2015) within 4h of after blood draw. Neutrophil function was assessed at the Birmingham Dental Hospital for reactive oxygen species (ROS) release by reaction with luminol (which measures total ROS release), isoluminol (which measures extracellular ROS release) and lucigenin (which measures superoxide release) (Dias et al., 2011; Matthews et al., 2007); chemotactic ability of the isolated cells for speed (movement in any direction), velocity (movement towards a chemoattractant) and chemotactic index (which records the accuracy of the cell movement) (Roberts et al., 2015); neutrophil extracellular trap production (Palmer et al., 2012) and release of matrix metalloproteinase 8 (Ling et al., 2015).

2.9 Statistical Analyses

Graphpad Prism (v 8) software were used for data analysis: Pearson correlations were used to construct the correlation matrix and heatmap.

3. Results

3.1 Dental examination

For this study 11 adult and one adolescent chimpanzee were examined. The age range of the cohort evaluated was between 10-53 years and comprised 3 males and 9 females. All data collected is summarised in table 1.

Visual examination of the hard and soft tissues of the oral cavity demonstrated generalised supragingival plaque and calculus deposits across all chimpanzees (for typical example see figure 1). Marginal inflammation was localised and bleeding only demonstrable on probing of the gingival sulcus. The gingival phenotype of the chimpanzees was thick with significant attached gingivae for both jaws, anterior and posterior with a distinct mucogingival junction. The entire permanent dentition had developed in all chimpanzees with all but one of the chimpanzees showing erupted third molars. One chimpanzee demonstrated an unerupted/congenitally missing LR2 as there was no history of extraction or exfoliation of this tooth (radiographic examination was not undertaken to exclude diagnosis of unerupted tooth). There was also evidence of carious/worn retained roots in two chimpanzees. No tooth loss was reported due to periodontitis and no teeth demonstrated tooth mobility. Generalised attritional tooth wear extending into dentine was evident in both maxillary and mandibular dentitions. One chimpanzee exhibited wear of an UL3 into pulpal tissue with an associated sinus tract as a result of pulpal exposure. The eldest chimpanzee in the study population demonstrated a carious retained root although in general the presence of dental caries was not detected clinically across the sample population. The maximum pocket depth recorded was 9mm and the mean probing pocket depth was 3.6mm. Bleeding scores ranged from 2.69-33.84% (mean 16.33% +/- 10.01) and plaque scores ranged from 63.71-100.00% (mean 85.28% +/- 10.90). Distribution of these recordings per tooth are summarised in figure 2. The mean PISA was found to be 411 mm^2 +/- 290 and PESA was 2071mm^2 +/- 495. The only cytokines that were detectable in GCF across all the chimpanzees were IL-1β and IL-8. These data are shown in Table 1. Detectable levels of IL-6 and TNF-α in GCF were found in only one and five chimpanzees respectively whilst no chimpanzees demonstrated detectable levels of IL-17A, thus these data are not reported.

3.2 Cardiac examination and biomarkers

Echocardiographic examinations were performed in the chimpanzees during anaesthesia. Several displayed at least a mild reduction in left ventricular function, that was difficult to separate from the effect of anaesthetic drugs and changes in blood pressure. However, in one chimp, very poor left

ventricular function was observed and was being monitored with an implantable loop recorder (Medtronic Reveal LINQ, Medtronic, UK). The latter animal died 24 months later from thrombosis in an arm. In another chimp a mild valvular aortic stenosis was detected. In the remaining animals no abnormalities were detected upon echocardiogram inspection.

Blood samples were analysed for quantity of circulating troponin and NT-proBNP as biomarkers of heart health. The female recorded to have very poor left ventricular function had higher NT-proBNP (3706 pg/ml); levels were not raised in the female with aortic stenosis. After these observations, there was no overwhelming clinical evidence of a systemic inflammatory condition or neoplastic process as far as assessable.

3.3 Neutrophil function

Isolated neutrophils were assessed for reactive oxygen species (ROS) production, chemotaxis and NETS formation in response to stimuli previously determined with human neutrophils. For ROS production the Toll-like receptor stimulus heat killed *Fusobacterium nucleatum* (FN) was used; for Fcγ receptor stimulation heat killed and opsonised *Staphylococcus aureus* (OpsSA) was used; additionally, neutrophils were treated with Phorbol 12-myristate 13-acetate (PMA) for non-receptor mediated stimulation or with phosphate buffered saline (PBS). FN, OpsSA and PMA all caused increases in ROS production as expected. For chemotaxis isolated cells were exposed to either bacterial peptide N-formyl-L-methionyl-L-leucyl-phenylalanine (FMLP) or PBS. FMLP caused a greater movement as measured by speed, velocity and chemotactic index (CI) in comparison to PBS exposed cells, as expected (table 1). NETS were stimulated by PMA, hypochlorous acid (HOCl) or PBS. PMA and HOCl induced more NETS than PBS as expected. All data are recorded in table 1.

Lutein, zeaxanthin, α-tocopherol and retinol were detectable in the serum of all chimpanzees. The remaining micronutrients (lycopene, α-carotene and β-carotene) were only found in traces, detectable in some of the chimpanzees, but not in all. Data for these markers are shown in Table 1.

3.4 Data correlation

From the data collected a correlation matrix was determined to explore the correlations between the different parameters measured. Figure 3 shows the results of this as a heatmap. Red represents positive correlations and blue negative correlations. Any significant correlations (after Bonferroni adjustment) are listed in Table 2.

3.5 Post mortem analysis

24 and 25 months respectively after the chimpanzees had been relocated 2 individuals suffered short illnesses and died. Following post mortem, it was possible to confirm that the two chimpanzees had heart disease. Both female chimpanzees in their early forties showed histopathological evidence of moderate to marked, multifocal to diffuse idiopathic myocardial fibrosis, a commonly identified, fatal, degenerative cardiac disease in captive chimpanzees of currently unknown aetiopathogenesis. These two animals had NT-proBNP at the higher end of the range of the cohort when samples at the time of relocation (see table 1 for comparison to mean and range of data): 3706ng/ml and 6814ng/ml.

4. Discussion

This study was possible due to the relocation of a cohort of captive chimpanzees to a new enclosure. During the relocation each animal was anaesthetised and a full health check was performed. This included a full oral examination, echocardiographic examination and blood sampling. It was also possible to gain further data following the death of two of the chimpanzees included in the study. Post mortem analysis showed conclusively that these two individuals had heart disease. This has given a unique opportunity to explore the data collected with this hard end point.

The oral health of the chimpanzees based on the observational and clinical measurements taken are similar to the findings of studies carried out in the 1970s where chimpanzee periodontal health was investigated. In a 1973 data set, 6 primates were assessed both clinically and radiographically. Radiographic analysis detected 25-40% bone loss by 44 years old with mean probing pocket depth being 3.25mm (Arnold & Baram, 1973). A subsequent study in 1975 by a different group provided similar clinical observations as well as describing a thick gingival phenotype. The mean pocket depth in this study was found to be 4.45mm in a population aged 27-49 years old (Page et al., 1975).

Our findings are not dissimilar to this with a comparable mean probing pocket depth of 3.59mm. During exploratory analyses significant correlations were found between mean age and probing pocket depth/PESA suggesting that in chimpanzees, like their human cousins, there is an increase in clinical attachment loss with age. Whether this is due to the ageing process per se or a result of other risk factors cumulating over time cannot be confirmed by results presented here. It must be considered, however, that some of the putative risk factors, for example smoking, that are associated with periodontitis in humans do not seem to be present in chimpanzees.

The one risk factor that is clear would be a lack of oral hygiene practice and this is evidenced with an average plaque score of 85.28% across the cohort. It is well established in human studies that increased biofilm leads to an increase in gingival inflammation (Loe et al., 1965). Despite such high plaque scores in the chimpanzee population, which one would assume would be chronic, a mean bleeding score of 16.33% was observed and this can be considered very low: almost approaching an accepted criteria of inflammatory stability in the human periodontium (Chapple et al., 2018). In human cohort studies where oral hygiene has not been controlled as a risk factor, longitudinal data has found differing susceptibilities ranging from minimal/no attachment loss to significant attachment loss including loss of teeth (Loe et al., 1986). Compared to these studies this chimpanzee population falls into the minimally affected groups rather than the highly susceptible groups demonstrating tooth loss.

Chimpanzees are omnivores: in this cohort they are provided with a diet mostly consisting of vegetables to limit sugar intake through fruit. Here the levels of lutein and zeaxanthin, alpha-tocopherol and retinol were all measurable. The pattern found in this study on chimpanzees reflects what was found when exploring the plasma carotenoid levels of monkeys (*Macaca fascicularis* and *Saimiri sciureus*) (Snodderly et al., 1990). However, it was not possible to measure lycopene and cryptoxanthin or carotenes in serum, which directly reflects the low quantity of fruits, such as tomatoes, provided. Levels of lutein, zeaxanthin were at the lower end of the range found in humans (Tudor & Pintea, 2020), levels of tocopherol were similar to those found in humans (Li et al., 2016), retinol levels were above that deemed as deficiency in humans (WHO, 2011).

PISA and PESA scores have been calculated in human studies looking at the relationship of periodontitis and systemic inflammation or diseases as it allows a quantifiable way to translate the potential of local inflammatory mediators or bacteria entering the systemic circulation. Values for PISA and PESA have been reported in the literature for humans. Definitions for human periodontitis patients defined by PISA are as healthy 10-63mm^2, mild periodontitis 110-227mm^2, moderate periodontitis 521-790mm^2 and severe periodontitis 934-3275mm^2 (Leira et al., 2018). Based on this, 4 chimpanzees would fall into the no or mild periodontitis group, four would be mild -moderate and 4 chimpanzees would be considered to have moderate-severe periodontitis in this study. This has the immediate limitation as being translated directly from humans to chimpanzees and that the high PISA, yet low overall bleeding score could be due to the thick gingival phenotype and method by which bleeding on scoring was measured.

GCF biomarkers, IL-8 and IL-1β, were detectable in all chimpanzees providing evidence for physiological mechanisms occurring in the periodontal apparatus of these primates which may mimic humans. This study is the first to provide evidence of specific biomarker presence in the GCF of chimpanzees. IL-1β is a heavily investigated biomarker in the GCF of humans and evidence has generally favoured an increase in IL-1β within the GCF of humans both in experimental gingivitis models as well as in patients with periodontitis (Heasman et al., 1993; Hou et al., 1995; Trombelli et al., 2010). The amount of IL-1β reported within these studies varies significantly and has been reported both higher and lower than those found in the chimpanzee population examined in this study. (Heasman et al., 1993) reported a mean value of 131 ng/ml one week into their experimental gingivitis model whilst (Trombelli et al., 2010) reported 25.2 pg/ml within their model. An investigation into IL-1β levels in periodontitis patients, prior to active therapy, reported mean values of up to 181.61 pg/ml (Hou et al., 1995). The findings of GCF IL-1β reported in our investigation falls in line with those studies investigating the experimental gingivitis models rather than in pre-

treatment periodontitis patients. This may support the theory that the inflammatory process in chimpanzees mimics a superficial gingivitis rather than a more destructive periodontitis and is backed up by the clinical findings in this population.

IL-8 is also an important and potent chemokine in the processes of inflammatory periodontal diseases as well as in clinical health. The main cellular target is the neutrophil, considered the major cell type in periodontitis. One recent systematic review has explored outcomes from studies investigating IL-8 in GCF, saliva and gingival tissues and was able to complete a meta-analysis for studies reporting IL-8 within GCF (Finoti et al., 2017). The meta-analysis found that lower levels of IL-8 were present in the GCF of chronic periodontitis compared with healthy individuals. The detectable levels of IL-8 suggest a similar neutrophil rich environment in the gingival tissues of chimpanzees.

For the neutrophil function explored here the assays used were assumed at outset to function comparatively between humans and chimpanzees as previously neutrophils from chimpanzees have been recognised to be morphologically indistinguishable from those of humans (Martin et al., 2011). All the assays performed as expected with the relevant stimuli causing expected increases. This suggests that between chimpanzees and humans there may be little difference in the functionality of neutrophils as determined here. Previously some differences have been highlighted: (Alvarez et al., 1996) and loss of ligand recognition in Siglec -14 and -5 (Angata et al., 2006) in chimpanzees compared to humans. Neutrophil function in humans with periodontitis has demonstrated hyper-activity and reactivity in the assays used here (Matthews et al., 2007; Roberts et al., 2015; Ling et al ., 2015). However, there were no surprising changes in neutrophil function and no assays demonstrated a correlation with the periodontal markers. This may be an effect of the small sample size and low incidence of periodontal disease in this cohort.

In the exploration of cardiac health in this cohort of chimpanzees serum levels of NT-proBNP and troponin, both acknowledged markers of heart health in humans, were measured alongside the assessment of heart health under anaesthesia by echocardiogram. The latter have the potential to be confounded by the use of anaesthesia and it is not possible to explore the effects of the anaesthesia easily as it is not possible to perform the tests on conscious chimpanzees. However, the cardiac data collection was as standardised as possible to limit variability in the data. At the time of the relocation of the animals and collection of the data the absolute status of the animals thought to be at risk was not verifiable. However, subsequently two of the animals assessed have died and this has been attributed at post mortem to heart disease. Even at time of relocation and blood sampling

these animals appeared to have NT-proBNP levels at the higher end of the cohort range. NT-proBNP may also serve as a biomarker for heart disease in chimpanzees as it does in humans.

In the correlation of the data collected, a few variables were identified as being significantly correlated (Table 2). The majority of these data demonstrate correlations between parameters that would be expected to be correlated (e.g. Mean pocket depth v PESA) as they have underlying contributions. To explore further non-significant correlation would be speculative however the data may be useful in driving laboratory-based hypotheses, for example in the histological exploration of cardiac samples for contributions by neutrophils or other immune cells in idiopathic myocardial fibrosis and cardiomyopathy such as explored by Strong et al., 2020.

There are a number of limitations with this study and several have been highlighted above. Most prominently the sample size described is small when put in the context of human studies. The cohort of apes is also heterogeneous in age (spanning 10-53 years) with differing oral status. However, this study represents an analysis of 12 out of the approximately 700 captive chimpanzees in Europe. Thus, whilst it is desirable to have a larger cohort from which to sample and study it is not easily achieved. The Ape Heart and Great Ape Heart Projects aim to coordinate collection of material on the great apes and a biobank has been established. However, there will never be as many samples as in human studies and there will always be a degree of heterogeneity. That all the animals studied here came from one zoo means that living conditions, exposure to sunlight and nutrition will be similar, which cannot always be said for human studies.

In conclusion this captive chimpanzee population demonstrates mild inflammatory periodontal disease and presents a picture of resistance to severe periodontal attachment loss despite high biofilm levels. The exposed epithelial surface area (inflamed or not) does not seem to correlate with the amount of local inflammatory mediators although specific mediators are present as in humans. Whilst serum biomarkers of heart health appear to be associated with heart disease, there seems little evidence for an association between heart disease and periodontal status in this cohort.

Acknowledgements

We acknowledge the contribution of TZ great ape keeping team and Twycross Zoo for making this study possible. We also acknowledge the contribution of Professor Mark Ide (KCL) for assistance in funding applications and calculation of PISA scores and Professor Iain Chapple (UoB) for assistance in GCF calibration training.

Funding

This project was funded by King's College London and the University of Birmingham. The relocation of the animals was supported by Twycross Zoo.

Tables:

Table 1. Data collected from all evaluations of the cross-sectional study of 12 chimpanzees. Data are presented as mean, standard deviation and 95% confidence intervals.

	Number of values	Mean	Std. Deviation	Lower 95% CI of mean	Upper 95% CI of mean
Age	12	31.1	11.7	24.3	37.8
Mean Pocket Depth (mm)	12	3.6	0.6	3.2	4.0
Maximum Pocket Depth (mm)	12	6.8	1.6	5.8	7.8
Bleeding Score (%)	12	16.3	10	10	22.7
Plaque Score	12	85.3	10.9	78.4	92.2
PESA	12	2072	496	1757	2386
PISA	12	411	291	226	596
IL-1βeta (pg/ml)	12	36.9	32.8	16.1	57.7
IL-8 (pg/ml)	12	183	247	25.8	340
PBS luminol (AU)	12	2174	1812	1022	3325
FN luminol (AU)	12	25352	11805	17851	32853
Ops SA luminol (AU)	12	90558	33353	69366	111749
PMA luminol (AU)	12	41078	18509	29318	52838
PBS isoluminol (AU)	12	594	474	293	896
FN isoluminol (AU)	12	4043	1896	2839	5248
Ops SA isoluminol (AU)	12	16111	3410	13945	18277
PMA isoluminol (AU)	12	22128	9215	16273	27983
PBS lucigenin (AU)	12	261	340	44.9	476
FN lucigenin (AU)	12	2314	1684	1244	3384
Ops SA lucigenin (AU)	12	5517	1567	4522	6513
PMA lucigenin (AU)	12	9205	4751	6186	12224
PBS speed (µm/min)	10	2.7	0.668	2.23	3.18
FMLP speed (µm/min)	10	4.11	1.38	3.12	5.09

PBS velocity (µm/min)	10	0.284	0.452	-0.0393	0.607
FMLP velocity (µm/min)	10	2.43	1.62	1.27	3.59
PBS CI (AU)	10	0.0857	0.141	-0.0153	0.187
FMLP CI (AU)	10	0.522	0.215	0.368	0.675
PBS NETS (AU)	11	130	45.2	99.9	161
PMA NETS (AU)	11	1723	1498	717	2729
HOCl NETS (AU)	11	6780	2294	5239	8322
Lutein (nmol/ml)	12	0.217	0.0988	0.154	0.28
Zeaxanthin (nmol/ml)	12	0.0518	0.0239	0.0366	0.067
Cryptoxanthin (nmol/ml)	8	0.0055	0.00239	0.0035	0.0075
Lycopene (total) (nmol/ml)	5	0.0246	0.0102	0.0119	0.0373
a-Carotene(nmol/ml)	4	0.0103	0.00236	0.00649	0.014
ß-Carotene (nmol/ml)	3	0.0157	0.00231	0.00993	0.0214
a-Tocopherol (nmol/ml)	12	16.7	4.4	13.9	19.5
Retinol (nmol/ml)	12	2.53	2.25	1.09	3.96
Vitamin D (nmol/L)	12	74.4	17.9	63.1	85.8
Weight (kg)	12	58	6.161	54.09	61.91
Body condition score (range 1-10)	12	4.9	1.1	4.2	5.6
Fructosamine (µmol/L)	12	215.6	26.8	198.6	232.6
HbA1C (mmol/mol)	12	24.5	1.6	23.5	25.5
NT-proBNP (ng/l)	12	1674	2114	330	3017
Troponin (ng/l)	12	74.8	66.5	32.6	117.1

Table 2. Significant correlations when comparing all the data. Data were compared by Pearson correlation. Bonferroni correction was used for multiple comparisons and padj<0.05 was used to select the data shown.

Comparison	Pearson R value	Number in comparison
Age v Mean pocket depth	0.846	12
Age v PESA	0.860	12
Mean pocket depth v PESA	0.980	12
Mean pocket depth v HbA1c	-0.828	12
Maximum pocket depth v HbA1c	-0.847	12
Bleeding Score v PISA	0.921	12
IL1beta v IL8	0.825	12
PBS luminol v PBS isoluminol	0.868	12
FN luminol v FN isoluminol	0.869	12
FN luminol v FN lucigenin	0.868	12
Ops SA luminol v PBS lucigenin	0.867	12
Ops SA luminol v FN lucigenin	0.862	12
Ops SA isoluminol v Ops SA lucigenin	0.839	12
PMA isoluminol v PMA lucigenin	0.865	12
PBS lucigenin v NT-proBNP	0.843	12
Ops SA lucigenin v Retinol	0.926	12
FMLP speed v FMLP velocity	0.931	12
PBS velocity v PBS CI	0.963	12
FMLP velocity v FMLP CI	0.980	9
Lutein v Zeaxanthin	0.935	12
LVEDV MOD A4C v LVESV MOD A4	0.909	12
LVFW long S v IVS long S	0.850	12

Figures:

Figure 1: Clinical image of anterior dentition demonstrating localised marginal inflammation around the UL2. Note also the significant band of attached keratinised gingiva and well defined mucogingival junction. Generalised attritional wear on the incisal surfaces through to dentine is evident.

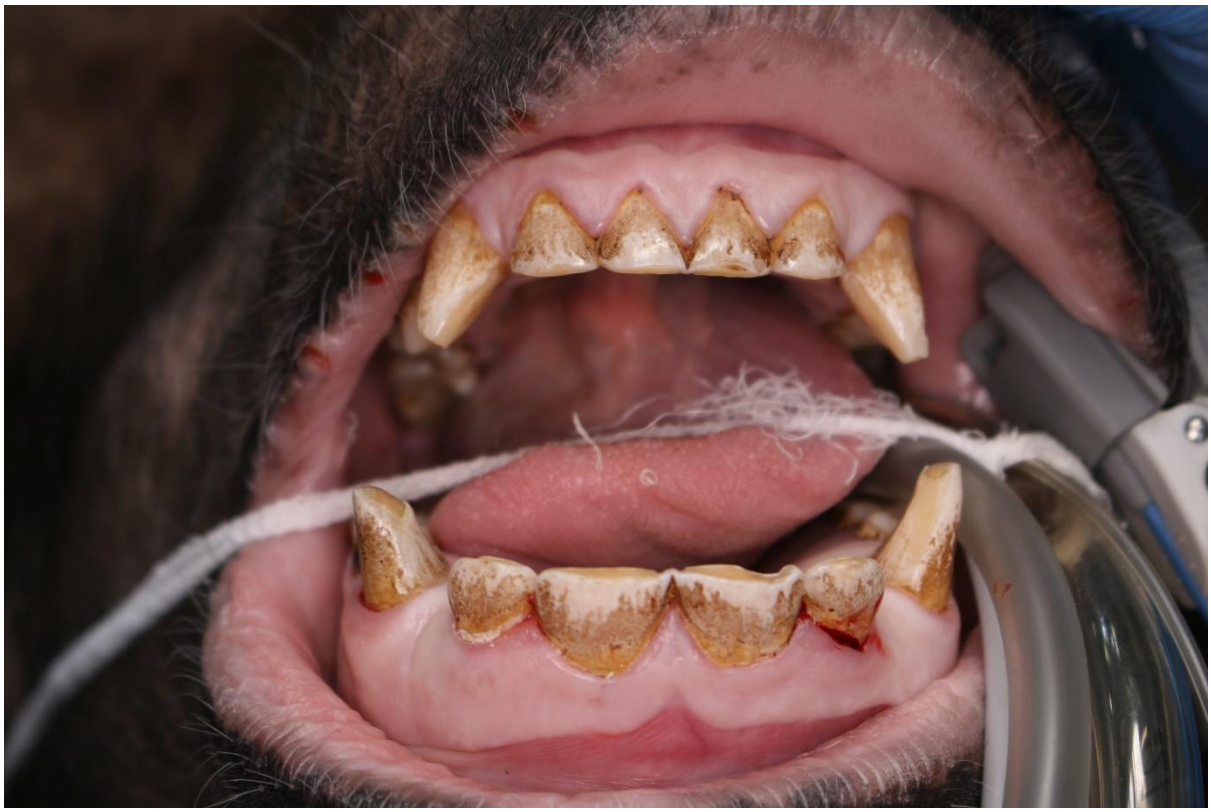

Figure 2 bar graphs showing the probing pocket depth (PPD), percentage of plaque sites and percentage of bleeding sites for the whole cohort by tooth: left hand side by upper and lower jaws and right hand side by buccal or lingual/palatal aspects of teeth.

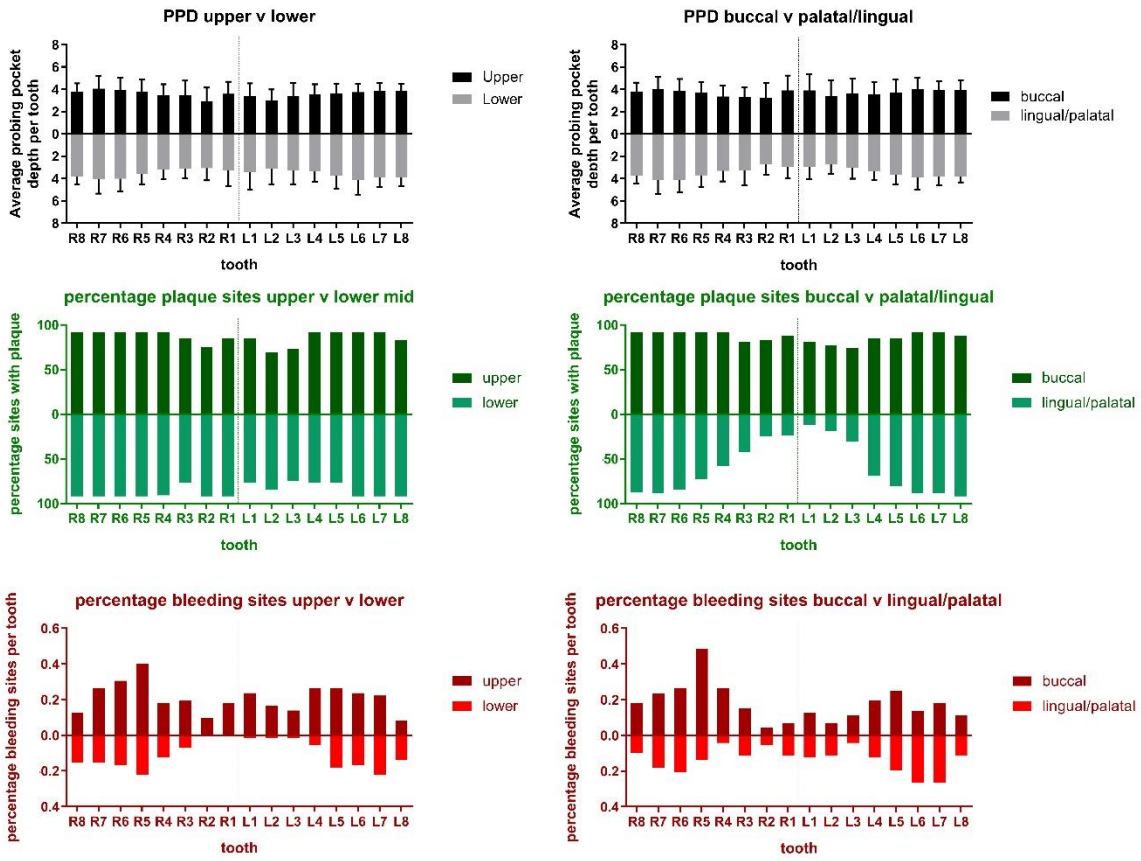

Figure 3 Correlation matrix heatmap for comparisons between all variables. Data were compared by Pearson correlation. Positive correlation is shown in red and negative correlation is shown in blue. Significant comparisons are listed in table 2.

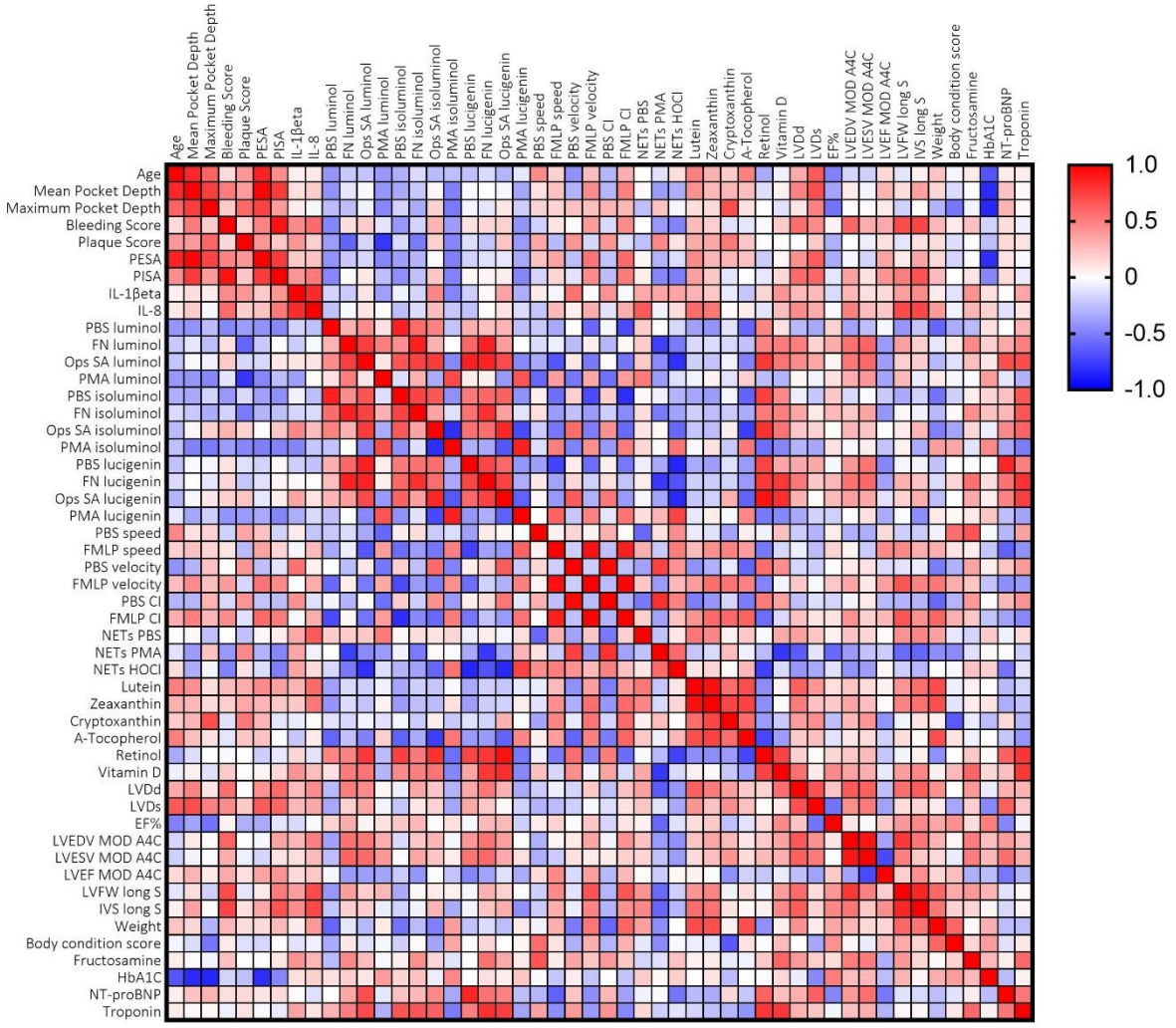

Table legends

Table 1. Data collected from all evaluations of the cross-sectional study of 12 chimpanzees. Data are presented as mean, standard deviation and 95% confidence intervals.

Table 2. Significant correlations when comparing all the data. Data were compared by Pearson correlation. Bonferroni correction was used for multiple comparisons and padj<0.05 was used to select the data shown.

References

Alvarez, V., Coto, E., Setien, F., Gonzalez-Roces, S., & Lopez-Larrea, C. (1996). Molecular evolution of the N-formyl peptide and C5a receptors in non-human primates. *Immunogenetics*, *44*(6), 446-452. https://doi.org/10.1007/BF02602806

Angata, T., Hayakawa, T., Yamanaka, M., Varki, A., & Nakamura, M. (2006). Discovery of Siglec-14, a novel sialic acid receptor undergoing concerted evolution with Siglec-5 in primates. *FASEB J*, *20*(12), 1964-1973. https://doi.org/10.1096/fj.06-5800com

Arnold, L., & Baram, P. (1973). Periodontal disease in chimpanzees. *J Periodontol*, *44*(7), 437-442. https://doi.org/10.1902/jop.1973.44.7.437

Baumgartner, S., Imfeld, T., Schicht, O., Rath, C., Persson, R. E., & Persson, G. R. (2009). The impact of the stone age diet on gingival conditions in the absence of oral hygiene. *J Periodontol*, *80*(5), 759-768. https://doi.org/10.1902/jop.2009.080376

Chapple, I. L., Glenwright, H. D., Matthews, J. B., Thorpe, G. H., & Lumley, P. J. (1994). Site-specific alkaline phosphatase levels in gingival crevicular fluid in health and gingivitis: cross-sectional studies. *J Clin Periodontol*, *21*(6), 409-414. https://doi.org/10.1111/j.1600-051x.1994.tb00738.x

Chapple, I. L., Landini, G., Griffiths, G. S., Patel, N. C., & Ward, R. S. (1999). Calibration of the Periotron 8000 and 6000 by polynomial regression. *J Periodontal Res*, *34*(2), 79-86. https://doi.org/10.1111/j.1600-0765.1999.tb02226.x

Chapple, I. L. C., Mealey, B. L., Van Dyke, T. E., Bartold, P. M., Dommisch, H., Eickholz, P., Geisinger, M. L., Genco, R. J., Glogauer, M., Goldstein, M., Griffin, T. J., Holmstrup, P., Johnson, G. K., Kapila, Y., Lang, N. P., Meyle, J., Murakami, S., Plemons, J., Romito, G. A., Shapira, L., Tatakis, D. N., Teughels, W., Trombelli, L., Walter, C., Wimmer, G., Xenoudi, P., & Yoshie, H. (2018). Periodontal health and gingival diseases and conditions on an intact and a reduced periodontium: Consensus report of workgroup 1 of the 2017 World Workshop on the Classification of Periodontal and Peri-Implant Diseases and Conditions. *J Periodontol*, *89 Suppl 1*, S74-S84. https://doi.org/10.1002/JPER.17-0719

Dias, I. H., Matthews, J. B., Chapple, I. L., Wright, H. J., Dunston, C. R., & Griffiths, H. R. (2011). Activation of the neutrophil respiratory burst by plasma from periodontitis patients is mediated by pro-inflammatory cytokines. *J Clin Periodontol*, *38*(1), 1-7. https://doi.org/10.1111/j.1600-051X.2010.01628.x

Dommisch, H., Kuzmanova, D., Jonsson, D., Grant, M., & Chapple, I. (2018). Effect of micronutrient malnutrition on periodontal disease and periodontal therapy. *Periodontol 2000*, *78*(1), 129-153. https://doi.org/10.1111/prd.12233

Eke, P. I., Wei, L., Borgnakke, W. S., Thornton-Evans, G., Zhang, X., Lu, H., McGuire, L. C., & Genco, R. J. (2016). Periodontitis prevalence in adults >/= 65 years of age, in the USA. *Periodontol 2000*, *72*(1), 76-95. https://doi.org/10.1111/prd.12145

Finoti, L. S., Nepomuceno, R., Pigossi, S. C., Corbi, S. C., Secolin, R., & Scarel-Caminaga, R. M. (2017). Association between interleukin-8 levels and chronic periodontal disease: A PRISMA-compliant systematic review and meta-analysis. *Medicine (Baltimore)*, *96*(22), e6932. https://doi.org/10.1097/MD.0000000000006932

Gombart, A. F., Pierre, A., & Maggini, S. (2020). A Review of Micronutrients and the Immune System-Working in Harmony to Reduce the Risk of Infection. *Nutrients*, *12*(1). https://doi.org/10.3390/nu12010236

Heasman, P. A., Collins, J. G., & Offenbacher, S. (1993). Changes in crevicular fluid levels of interleukin-1 beta, leukotriene B4, prostaglandin E2, thromboxane B2 and tumour necrosis factor alpha in experimental gingivitis in humans. *J Periodontal Res*, *28*(4), 241-247. https://doi.org/10.1111/j.1600-0765.1993.tb02090.x

Hou, L. T., Liu, C. M., & Rossomando, E. F. (1995). Crevicular interleukin-1 beta in moderate and severe periodontitis patients and the effect of phase I periodontal treatment. *J Clin Periodontol*, *22*(2), 162-167. https://doi.org/10.1111/j.1600-051x.1995.tb00128.x

Lammey, M. L., Baskin, G. B., Gigliotti, A. P., Lee, D. R., Ely, J. J., & Sleeper, M. M. (2008). Interstitial myocardial fibrosis in a captive chimpanzee (Pan troglodytes) population. *Comp Med*, *58*(4), 389-394. https://www.ncbi.nlm.nih.gov/pubmed/18724782

Leira, Y., Martin-Lancharro, P., & Blanco, J. (2018). Periodontal inflamed surface area and periodontal case definition classification. *Acta Odontol Scand*, *76*(3), 195-198. https://doi.org/10.1080/00016357.2017.1401659

Li, G., Li, Y., Chen, X., Sun, H., Hou, X., & Shi, J. (2016). Circulating tocopherols and risk of coronary artery disease: A systematic review and meta-analysis. *Eur J Prev Cardiol*, *23*(7), 748-757. https://doi.org/10.1177/2047487315595313

Ling, M. R., Chapple, I. L., & Matthews, J. B. (2015). Peripheral blood neutrophil cytokine hyper-reactivity in chronic periodontitis. *Innate Immun*, *21*(7), 714-725. https://doi.org/10.1177/1753425915589387

Loe, H., Anerud, A., Boysen, H., & Morrison, E. (1986). Natural history of periodontal disease in man. Rapid, moderate and no loss of attachment in Sri Lankan laborers 14 to 46 years of age. *J Clin Periodontol*, *13*(5), 431-445. https://doi.org/10.1111/j.1600-051x.1986.tb01487.x

Loe, H., Theilade, E., & Jensen, S. B. (1965). Experimental Gingivitis in Man. *J Periodontol*, *36*, 177-187. https://doi.org/10.1902/jop.1965.36.3.177

Lowenstine, L. J., McManamon, R., & Terio, K. A. (2016). Comparative Pathology of Aging Great Apes: Bonobos, Chimpanzees, Gorillas, and Orangutans. *Vet Pathol*, *53*(2), 250-276. https://doi.org/10.1177/0300985815612154

Martin, D. I., Singer, M., Dhahbi, J., Mao, G., Zhang, L., Schroth, G. P., Pachter, L., & Boffelli, D. (2011). Phyloepigenomic comparison of great apes reveals a correlation between somatic and germline methylation states. *Genome Res*, *21*(12), 2049-2057. https://doi.org/10.1101/gr.122721.111

Matthews, J. B., Wright, H. J., Roberts, A., Cooper, P. R., & Chapple, I. L. (2007). Hyperactivity and reactivity of peripheral blood neutrophils in chronic periodontitis. *Clin Exp Immunol*, *147*(2), 255-264. https://doi.org/10.1111/j.1365-2249.2006.03276.x

Moittie, S., Graham, P. A., Barlow, N., Dobbs, P., Liptovszky, M., Redrobe, S., & White, K. (2020). Comparison of 25-hydroxyvitamin D concentration in chimpanzee dried blood spots and serum. *Vet Clin Pathol*, *49*(2), 299-306. https://doi.org/10.1111/vcp.12863

Munson, L., & Montali, R. J. (1990). Pathology and Diseases of Great Apes at the National-Zoological-Park. *Zoo Biology*, *9*(2), 99-105. <Go to ISI>://WOS:A1990CZ54300003

Nunamaker, E. A., Lee, D. R., & Lammey, M. L. (2012). Chronic diseases in captive geriatric female Chimpanzees (Pan troglodytes). *Comp Med*, *62*(2), 131-136. https://www.ncbi.nlm.nih.gov/pubmed/22546920

Page, R. C., Simpson, D. M., & Ammons, W. F. (1975). Host tissue response in chronic inflammatory periodontal disease IV. The periodontal and dental status of a group of aged great apes. *J Periodontol*, *46*(3), 144-155. https://doi.org/10.1902/jop.1975.46.3.144

Palmer, L. J., Cooper, P. R., Ling, M. R., Wright, H. J., Huissoon, A., & Chapple, I. L. (2012). Hypochlorous acid regulates neutrophil extracellular trap release in humans. *Clin Exp Immunol*, *167*(2), 261-268. https://doi.org/10.1111/j.1365-2249.2011.04518.x

Roberts, H. M., Ling, M. R., Insall, R., Kalna, G., Spengler, J., Grant, M. M., & Chapple, I. L. (2015). Impaired neutrophil directional chemotactic accuracy in chronic periodontitis patients. *J Clin Periodontol*, *42*(1), 1-11. https://doi.org/10.1111/jcpe.12326

Snodderly, D. M., Russett, M. D., Land, R. I., & Krinsky, N. I. (1990). Plasma carotenoids of monkeys (Macaca fascicularis and Saimiri sciureus) fed a nonpurified diet. *J Nutr*, *120*(12), 1663-1671. https://doi.org/10.1093/jn/120.12.1663

Stahl, W., Sundquist, A. R., Hanusch, M., Schwarz, W., & Sies, H. (1993). Separation of beta-carotene and lycopene geometrical isomers in biological samples. *Clin Chem*, *39*(5), 810-814. https://www.ncbi.nlm.nih.gov/pubmed/8485871

Strong, V., Moittie, S., Sheppard, M. N., Liptovszky, M., White, K., Redrobe, S., Cobb, M., & Baiker, K. (2020). Idiopathic Myocardial Fibrosis in Captive Chimpanzees (Pan troglodytes). *Vet Pathol*, *57*(1), 183-191. https://doi.org/10.1177/0300985819879442

Strong, V. J., Grindlay, D., Redrobe, S., Cobb, M., & White, K. (2016). A Systematic Review of the Literature Relating to Captive Great Ape Morbidity and Mortality. *J Zoo Wildl Med*, *47*(3), 697-710. https://doi.org/10.1638/2015-0240.1

Strong, V. J., Sheppard, M. N., Redrobe, S., & Baiker, K. (2018). Guidelines for consistent cardiovascular post-mortem examination, sampling and reporting of lesions in European zoo-housed great apes. *International Zoo Yearbook*, *52*(1), 126-136. <Go to ISI>://ZOOREC:ZOOR15412088079

TAG, A. A. (2010). *CHIMPANZEE (Pan troglodytes) CARE MANUAL*.

Tonetti, M. S., Van Dyke, T. E., & working group 1 of the joint, E. F. P. A. A. P. w. (2013). Periodontitis and atherosclerotic cardiovascular disease: consensus report of the Joint EFP/AAP Workshop on Periodontitis and Systemic Diseases. *J Periodontol*, *84*(4 Suppl), S24-29. https://doi.org/10.1902/jop.2013.1340019

Trombelli, L., Scapoli, C., Carrieri, A., Giovannini, G., Calura, G., & Farina, R. (2010). Interleukin-1 beta levels in gingival crevicular fluid and serum under naturally occurring and experimentally induced gingivitis. *J Clin Periodontol*, *37*(8), 697-704. https://doi.org/10.1111/j.1600-051X.2010.01573.x

Tudor, C., & Pintea, A. (2020). A Brief Overview of Dietary Zeaxanthin Occurrence and Bioaccessibility. *Molecules*, *25*(18). https://doi.org/10.3390/molecules25184067

WHO. (2011). https://www.who.int/vmnis/indicators/retinol.pdf

Wu, Y., Li, Y., Zhang, C., A, X., Wang, Y., Cui, W., Li, H., & Du, J. (2014). S100a8/a9 released by CD11b+Gr1+ neutrophils activates cardiac fibroblasts to initiate angiotensin II-Induced cardiac inflammation and injury. *Hypertension*, *63*(6), 1241-1250. https://doi.org/10.1161/HYPERTENSIONAHA.113.02843